


# Radiofrequency ablation and related ultrasound-guided ablation technologies for treatment of benign and malignant thyroid disease: An international multidisciplinary consensus statement of the American Head and Neck Society Endocrine Surgery Section with the Asia Pacific Society of Thyroid Surgery, Associazione Medici Endocrinologi, British Association of Endocrine and Thyroid Surgeons, European Thyroid Association, Italian Society of Endocrine Surgery Units, Korean Society of Thyroid Radiology, Latin American Thyroid Society, and Thyroid Nodules Therapies Association

Lisa A. Orloff MD<sup>1</sup> | Julia E. Noel MD<sup>1</sup>  | Brendan C. Stack Jr MD<sup>2</sup>  |  
 Marika D. Russell MD<sup>3</sup> | Peter Angelos MD, PhD<sup>4</sup> | Jung Hwan Baek MD, PhD<sup>5</sup> |  
 Kevin T. Brumund MD<sup>6</sup> | Feng-Yu Chiang MD<sup>7</sup> | Mary Beth Cunnane MD<sup>8</sup> |  
 Louise Davies MD<sup>9</sup>  | Andrea Frasoldati MD<sup>10</sup> | Anne Y. Feng BS<sup>11</sup> |  
 Laszlo Hegedüs MD<sup>12</sup> | Ayaka J. Iwata MD<sup>13</sup> | Emad Kandil MD<sup>14</sup>  |  
 Jennifer Kuo MD<sup>15</sup> | Celestino Lombardi MD<sup>16</sup> | Mark Lupo MD<sup>17</sup> |  
 Ana Luiza Maia MD, PhD<sup>18</sup> | Bryan McIver MD, PhD<sup>19</sup> |  
 Dong Gyu Na MD, PhD<sup>20</sup>  | Roberto Novizio MD<sup>21</sup> | Enrico Papini MD<sup>22</sup> |  
 Kopal N. Patel MD<sup>23</sup> | Leonardo Rangel MD<sup>24</sup> | Jonathon O. Russell MD<sup>25</sup>  |  
 Jennifer Shin MD<sup>11</sup> | Maisie Shindo MD<sup>26</sup> | David C. Shonka Jr MD<sup>27</sup> |  
 Amanda S. Karcioglu MD<sup>28,29</sup> | Catherine Sinclair MD<sup>30</sup> |  
 Michael Singer MD<sup>31</sup>  | Stefano Spiezia MD<sup>32</sup> | Jose Higino Steck MD, PhD<sup>33</sup>  |  
 David Stewart MD<sup>34</sup> | Kyung Tae MD, PhD<sup>35</sup>  | Neil Tolley MD<sup>36</sup> |  
 Roberto Valcavi MD<sup>21</sup> | Ralph P. Tufano MD<sup>25</sup> | R. Michael Tuttle MD<sup>37</sup> |  
 Erivelto Volpi MD, PhD<sup>38</sup> | Che Wei Wu MD, PhD<sup>39</sup> |  
 Amr H. Abdelhamid Ahmed MBBCH<sup>40</sup> | Gregory W. Randolph MD<sup>40</sup>

<sup>1</sup>Department of Otolaryngology – Head & Neck Surgery, Stanford University School of Medicine, Stanford, California, USA

<sup>2</sup>Department of Otolaryngology – Head & Neck Surgery, Southern Illinois University School of Medicine, Springfield, Illinois, USA

<sup>3</sup>Department of Otolaryngology – Head & Neck Surgery, San Francisco School of Medicine, University of California, San Francisco, California, USA

<sup>4</sup>Department of Surgery, University of Chicago, Chicago, Illinois, USA

- <sup>5</sup>Department of Radiology, Research Institute of Radiology, Asan Medical Center, University of Ulsan College of Medicine, Seoul, South Korea
- <sup>6</sup>Division of Otolaryngology – Head and Neck Surgery, Department of Surgery, University of California, San Diego, San Diego, California, USA
- <sup>7</sup>Department of Otolaryngology – Head and Neck Surgery, E-Da Hospital, School of Medicine, College of Medicine, I-Shou University, Kaohsiung, Taiwan
- <sup>8</sup>Department of Radiology, Massachusetts Eye and Ear Infirmary, Harvard Medical School, Boston, Massachusetts, USA
- <sup>9</sup>The Section of Otolaryngology, The Dartmouth Institute for Health Policy and Clinical Practice, Geisel School of Medicine at Dartmouth, Hanover, New Hampshire, USA
- <sup>10</sup>Department of Endocrinology and Metabolism, Arcispedale Santa Maria Nuova IRCCS-ASL, Reggio Emilia, Italy
- <sup>11</sup>Department of Otolaryngology – Head and Neck Surgery, Brigham & Women's Hospital, Harvard Medical School, Boston, Massachusetts, USA
- <sup>12</sup>Department of Endocrinology and Metabolism, Odense University Hospital, Odense, Denmark
- <sup>13</sup>Department of Otolaryngology – Head & Neck Surgery, Kaiser Permanente, Santa Clara, California, USA
- <sup>14</sup>Department of Surgery, Tulane University School of Medicine, New Orleans, Louisiana, USA
- <sup>15</sup>Department of Surgery, Columbia University Irving Medical Center, New York, New York, USA
- <sup>16</sup>Division of Endocrine and Metabolic Surgery, Fondazione Policlinico Universitario A. Gemelli IRCCS, Rome, Italy
- <sup>17</sup>Thyroid & Endocrine Center of Florida, Sarasota, Florida, USA
- <sup>18</sup>Unidade de Tireoide, Hospital de Clínicas de Porto Alegre, Faculdade de Medicina, Universidade Federal do Rio Grande do Sul, Porto Alegre, Brazil
- <sup>19</sup>Department of Head and Neck-Endocrine Oncology, H. Lee Moffitt Cancer Center, Research Institute, Tampa, Florida, USA
- <sup>20</sup>Department of Radiology, Gangneung Asan Hospital, University of Ulsan College of Medicine, Gangneung, South Korea
- <sup>21</sup>Endocrine & Thyroid Clinic (E.T.C.), Reggio Emilia, Italy
- <sup>22</sup>Department of Endocrinology and Metabolism, Regina Apostolorum Hospital, Rome, Italy
- <sup>23</sup>Department of Surgery, New York University, New York, New York, USA
- <sup>24</sup>Division of Otorhinolaryngology – Head and Neck Surgery, State University of Rio de Janeiro, Rio de Janeiro, Brazil
- <sup>25</sup>Department of Otolaryngology – Head and Neck Surgery, Johns Hopkins University School of Medicine, Baltimore, Maryland, USA
- <sup>26</sup>Department of Otolaryngology – Head and Neck Surgery, Oregon Health and Science University, Portland, Oregon, USA
- <sup>27</sup>Department of Otolaryngology – Head and Neck Surgery, University of Virginia Health System, Charlottesville, Virginia, USA
- <sup>28</sup>Division of Otolaryngology – Head and Neck Surgery, Department of Surgery, NorthShore University Health System, Evanston, Illinois, USA
- <sup>29</sup>Clinician Educator, Pritzker School of Medicine, Chicago, Illinois, USA
- <sup>30</sup>Department of Otolaryngology – Head and Neck Surgery, Mount Sinai West Hospital, New York, New York, USA
- <sup>31</sup>Department of Otolaryngology – Head and Neck Surgery, Henry Ford Health System, Detroit, Michigan, USA
- <sup>32</sup>Endocrine Surgery, Ospedale del Mare, ASL NA1 Centro, Naples, Italy
- <sup>33</sup>Department of Otorhinolaryngology – Head and Neck Surgery, University of Campinas, Campinas, Brazil
- <sup>34</sup>Department of Otolaryngology – Head and Neck Surgery, University of Cincinnati, Cincinnati, Ohio, USA
- <sup>35</sup>Department of Otolaryngology – Head and Neck Surgery, College of Medicine, Hanyang University, Seoul, South Korea
- <sup>36</sup>Hammersmith Hospital, Imperial College NHS Healthcare Trust, London, UK
- <sup>37</sup>Endocrine Service, Department of Medicine, Memorial Sloan Kettering Cancer Center, New York, New York, USA
- <sup>38</sup>Oncology Center, Oswaldo Cruz German Hospital, Sao Paulo, Brazil
- <sup>39</sup>Department of Otolaryngology – Head and Neck Surgery, Kaohsiung Medical University Hospital, Faculty of Medicine, College of Medicine, Kaohsiung Medical University, Kaohsiung, Taiwan
- <sup>40</sup>Department of Otolaryngology – Head and Neck Surgery, Division of Thyroid and Parathyroid Endocrine Surgery, Massachusetts Eye & Ear Infirmary, Harvard Medical School, Boston, Massachusetts, USA

### Correspondence

Julia E. Noel, Stanford University School of Medicine, 875 Blake Wilbur Drive CC-2225, Stanford, CA 94305, USA.  
Email: jnoel@stanford.edu

### Abstract

**Background:** The use of ultrasound-guided ablation procedures to treat both benign and malignant thyroid conditions is gaining increasing interest. This document has been developed as an international interdisciplinary evidence-based statement with a primary focus on radiofrequency ablation and is intended to serve as a manual for best practice application of ablation technologies.

**Methods:** A comprehensive literature review was conducted to guide statement development and generation of best practice recommendations. Modified Delphi method was applied to assess whether statements met consensus among the entire author panel.

**Results:** A review of the current state of ultrasound-guided ablation procedures for the treatment of benign and malignant thyroid conditions is presented. Eighteen best practice recommendations in topic areas of preprocedural evaluation, technique, postprocedural management, efficacy, potential complications, and implementation are provided.

**Conclusions:** As ultrasound-guided ablation procedures are increasingly utilized in benign and malignant thyroid disease, evidence-based and thoughtful application of best practices is warranted.

#### KEYWORDS

international consensus, radiofrequency ablation, thermal ablation, thyroid ablation, ultrasound-guided ablation

## 1 | INTRODUCTION

There is growing global interest in ultrasound (US)-guided ablation procedures for treating benign and malignant thyroid conditions. These procedures are performed by surgeons, radiologists, and endocrinologists, and clinical practice guidelines have recently been published by several representative professional societies.<sup>1–5</sup> Given this multidisciplinary and international development, there is a pressing need to identify best clinical practices. The standardization of terminology and reporting criteria has been emphasized as a critical component of this process.<sup>6,7</sup>

This document has been developed as an interdisciplinary international statement primarily addressing radiofrequency ablation (RFA), as this technology has garnered significant recent interest and is associated with robust literature. Laser thermal ablation (LTA) and ethanol ablation are well-established practices also associated with significant evidence. Other emerging technologies, including microwave ablation (MWA), and high-intensity focused ultrasound (HIFU) are gaining in popularity and warrant evaluation.

With the increasing use of ablation technologies across a variety of clinical settings, it is important to define criteria for the candidacy of patients undergoing these procedures. Such criteria permit assessment of efficacy and promote the judicious use of evolving technologies. This document will address use of ablation technologies in benign and malignant conditions which have accrued adequate evidence and received sufficient attention in the literature; such benign conditions include nodules with compressive symptoms, cosmetic disturbance, or autonomously functioning thyroid

nodules. Malignant conditions include recurrent thyroid malignancy (in the thyroid remnant or in lymph nodes) and small, low-risk primary thyroid cancers.

Importantly, an established skill set in the performance of US and US-guided procedures is a prerequisite for the safe application of US-guided ablation technologies. This document does not supplant this essential foundational experience, but rather is intended to serve as a resource to reduce variation in practice, support delivery of highest quality care, and promote responsible global dissemination of these technologies.<sup>8</sup> Collectively, the recommendations provided are intended to offer a manual for best practice application of ablation technologies.

## 2 | BACKGROUND

### 2.1 | Principles of thermal ablation

All thermal ablation techniques are based upon the destruction of tissue in extreme hyperthermic conditions. The primary mechanism of cell death is coagulation necrosis. Below 40°C, cellular damage is reversible without long term effect.<sup>9,10</sup> Between 50 and 60°C, irreversible injury is induced, occurring more rapidly as temperature increases. Fixed ablation techniques often seek to maintain temperatures in this range for 4–6 min. Beyond 60°C, protein denaturation and cellular membrane disruption result in near immediate tissue necrosis, and is the premise for the moving shot technique used in RFA.<sup>9,10</sup> Above 100–110°C, tissue vaporization and carbonization occur, creating gas around the electrode that

may result in insulation, limiting ablation efficacy.<sup>11,12</sup> Thermal ablation techniques are differentiated based on the method used to develop this temperature differential.

## 2.2 | Radiofrequency ablation

RFA destroys targeted tissue through a combination of frictional and conduction heat<sup>11</sup> generated from high-frequency alternating electric current oscillating between 200 and 1200 kHz.<sup>9,13</sup> Frictional heat is created when the RF waves pass through an electrode, agitating tissue ions as they try to follow the changes in direction of the alternating current. The result is an increase in the temperature of the surrounding tissue within a few millimeters of the electrode.<sup>9,12,13</sup> Heat conduction from the ablated area yields slower additional thermal damage to the target tissue and, eventually, tissue further from the electrode.

Specific to the thyroid, the use of the moving shot technique minimizes the conductive effect, and thermal energy is primarily generated via frictional heat.<sup>14</sup> In monopolar mode, the patient becomes part of a closed-loop circuit that includes the generator, electrode needle, and two grounding pads that disperse energy. In bipolar mode, the current is limited to the needle tip and does not pass through the patient. RFA-induced tissue damage depends on both tissue temperature and duration of heating,<sup>10,12</sup> summarized by the equation,<sup>9</sup>

$$\begin{aligned} \text{Coagulation necrosis} &= \text{energy deposited} \\ &\quad \times \text{local tissue interaction} \\ &\quad - \text{heat lost.} \end{aligned}$$

Perfusion-mediated tissue cooling from adjacent blood flow, known as the heat sink effect, as well as heterogeneity in target tissue (from calcification, fibrosis, or the presence of fluid) may affect the conduction of electricity and heat, thereby reducing RFA efficacy.<sup>12</sup>

## 2.3 | Laser ablation

LTA is another method of delivering thermal energy that has been applied to thyroid nodules.<sup>3</sup> A laser is a focused beam of light energy delivered through an optical fiber into the target tissue.<sup>15</sup> Local tissue effects can occur through various mechanisms, but LTA in the thyroid results from photon scatter generating heat transfer.<sup>12</sup> Energy absorption is nonlinear, temperature-dependent, and results in unique characteristics that can be manipulated and adjusted to be tumor- and patient-specific.<sup>16</sup> There are various laser sources, optical fibers, and wavelengths currently available. The most commonly described

configuration used for LTA of the thyroid is the Nd:YAG or Diode laser with an emission wavelength of 1064 nm, combined with planning and simulation software.<sup>12</sup> Relative to other thermal ablation techniques, LTA delivers less total energy, which may confer greater safety and control in critical areas.<sup>3</sup>

## 2.4 | Microwave ablation

Another hyperthermic ablation technique, MWA relies on generation of an electromagnetic field with wavelengths between 0.03 and 30 cm and frequency between 900 and 2500 MHz to cause oscillation of polarized ions, specifically water (H<sub>2</sub>O).<sup>17</sup> This oscillation creates friction and thus increases the local temperature.<sup>18</sup> Because an electromagnetic field is used instead of an electrical current, electrical conduction is not necessary. As such, the thermal spread is not as impeded by char or heat sink as with RFA.<sup>19</sup> Generally, a needle-like antenna is used to propagate the current, and multiple antennae may be used together. When multiple antennae are phased, the end result is an exponential increase in heating. Therefore, MWA offers the ability to deliver more thermal energy in a shorter time, resulting in a higher final tissue temperature.<sup>18</sup> This reduction in treatment time may be more valuable when treating larger tumors. Because MWA is especially effective in large tumors and in tissues that desiccate and then impede electrical currents, MWA is gaining popularity in some organ systems such as the liver, lungs, and bone.<sup>20,21</sup>

In the thyroid and compact anatomy of the central neck, it is possible that these factors represent disadvantages: rapid heating that is less responsive to heat sink may explain complications described in some early series.<sup>3,22-24</sup> These complications have been avoided in more recent series, however.<sup>22,25,26</sup>

## 2.5 | High-intensity focused ultrasound

HIFU is a unique noninvasive modality that uses sound waves as carriers to target a specific lesion or focus. Low-intensity sound waves are nondestructive and form the basis of applications such as those in physiotherapy, which stimulate or accelerate natural physiologic response to injury.<sup>27</sup> High-intensity ultrasound, however, transfers sufficient energy to induce coagulative necrosis via thermal and mechanical injury.<sup>28</sup> The thermal effect is achieved by the conversion of the energy generated by intense tissue vibration into frictional heat. Absorption within a focal target area creates high temperatures locally, and immediate cell death occurs once exceeding 55–60 °C. At this temperature, water within tissue vaporizes, and microbubbles begin to

form. Microbubble expansion and then collapse leads to mechanical damage to and hemorrhage within nearby cells through the cavitation process.<sup>29</sup> A key component and challenge of HIFU is the delivery of energy to a small area without causing damage to intervening and surrounding tissues. This is accomplished by focusing high-intensity waves from numerous sources outside the body onto the same target, avoiding significant energy accumulation in the propagation path.<sup>30</sup>

## 2.6 | Alcohol (ethanol) ablation

Intratumoral administration of ethanol was developed as a surgical alternative for treating hepatocellular carcinoma and has subsequently been applied across a variety of benign and malignant pathologies.<sup>31–35</sup> As a chemical ablation technique, ethanol promotes tissue destruction via two methods. The first is via cellular dehydration, leading to protein denaturation and the induction of coagulation necrosis. The second occurs when ethanol enters local circulation, causing damage to the vascular endothelium and platelet aggregation with fibrin clot formation, ultimately resulting in vascular thrombosis and tissue ischemia.<sup>36</sup> For this reason, targeting vascularity in solid and functional nodules has been proposed as a treatment strategy.<sup>37</sup>

Because of the variability in diffusion of ethanol from the site of injection, ablation efficacy can be unpredictable; ethanol leakage into cervical tissues may induce sharp pain and late fibrosis. Studies tracking distribution volume of ethyl alcohol within tumors show off-target leakage limits the uniform distribution and local retention of the agent, particularly within larger tumors.<sup>38</sup> For these reasons, multiple treatments are often required, and ablation is more successful in small, encapsulated lesions that provide a physical barrier to diffusion, maintaining concentration of ethanol within the interior.<sup>39,40</sup> Chemical ablation may also play an adjuvant role in combination with thermal therapies.<sup>41–43</sup> Ethanol ablation alone is most effective in the treatment of predominantly cystic nodules and has been largely abandoned as a treatment method for solid nodules.

## 3 | METHODS

### 3.1 | Author panel selection

An author panel was carefully selected to represent surgeons, radiologists and endocrinologists internationally with expertise in US-guided ablation procedures, as well as experts in research methodology. Authors representing

the American Head and Neck Society – Endocrine Section (AHNS-ES), Asia Pacific Society of Thyroid Surgery (APTS), Associazione Medici Endocrinologi (AME), British Association of Endocrine and Thyroid Surgeons (BAETS), European Thyroid Association (ETA), Italian Society of Endocrine Surgery Units (SIUEC), Korean Society of Thyroid Radiology (KSThR), Latin American Thyroid Society (LATS), and Thyroid Nodules Therapies Association (TNT) were selected to facilitate collaboration within this international and interdisciplinary group of societies.

### 3.2 | Literature search and evaluation approach

A subset of authors (JN, LAO, MR, BCS, GR) conducted a hand search of literature addressing ablation technologies in the treatment of thyroid conditions and iteratively generated a structured topic outline to guide manuscript development. Topics were selected and organized to construct a document that would serve as a manual for best clinical practice, with topic areas representing phases of care and areas of information guiding clinical decision-making. Further delineation of topic areas was informed by the collective experiential knowledge of the group. After iterative development by this subset of authors, the structured topic outline was shared with the entire author panel for further refinement.

A comprehensive literature search was conducted to identify articles addressing ablation procedures in the treatment of benign and malignant thyroid conditions. GR and MR identified eight sentinel articles to guide the search,<sup>1,2,12,44–48</sup> which was performed by a medical librarian. Sentinel articles were selected because they represented material addressing the clinical application of ablation technologies in the thyroid gland, including practical information and data on outcomes. Detailed search strategy and results are listed in Appendix. The medical librarian-directed search queried Medline via New PubMed (1946 [inception]–July 31, 2020), Embase.com (1947[inception]–July 31, 2020), Web of Science Core Collection (1900 [inception]–July 31, 2020), Cochrane Library, and clinicaltrials.gov, using search strategies customized for each database. The search utilized a combination of controlled vocabulary and keywords focused on the concepts: “ablation techniques” and “thyroid gland” (Appendix I: PubMed search strategy). Nonhuman studies were excluded. No filters for language, study design, or date of publication were used. To be included, articles had to be focused on thyroid and pertaining to the following ablation technologies: RF, HIFU, laser, MW, and ethanol. Articles addressing ablation of the

parathyroid glands or other tissues were excluded, as were articles without direct relevance for clinical application. Titles and abstracts were screened independently by GR and MR. Full-text articles were accessed if the appropriateness of inclusion could not be readily determined from the abstract alone. Disagreements were settled by discussion and consensus. After review, a total of 690 articles remained for qualitative synthesis. All articles were provided in full-text form in an online database for the entire author panel to access. Search results were supplemented with articles of importance identified by hand search, with all authors invited to contribute.

### 3.3 | Proposed statement development

In the next phase, “Best Practice Recommendation” statements were derived. The author groups assigned to each topic area summarized the literature and critically evaluated findings in light of their applicability to broad practice. They generated dialogue among themselves as they analyzed the data through sharing of draft documents for group review. Finally, a video conference was held for each author group to facilitate final discussion and closure.

### 3.4 | Modified Delphi method

A modified Delphi method was applied to assess whether statements achieved consensus.<sup>49,50</sup> An electronic survey was distributed to the full panel, and members were expected to complete their responses without knowing the responses of others in the group. The results were then analyzed using a numerical Likert scale with the following anchor points: 1 (*strongly disagree*); 3 (*disagree*); 5 (*neutral*); 7 (*agree*); and 9 (*strongly agree*). Statements were defined as achieving consensus if there was a mean score of 7.0 or greater and 0–2 outlier responses, or a mean greater than or equal to 7.0 and 3 outliers with no outlier value lower than 5 (*neutral*). Nonconsensus was the default if these criteria were not met. Outlier responses were defined as any rating at least 2 Likert points away from the mean. Statistical analysis was performed utilizing Stata 15.0 (College Station, TX). Based on the results of this initial round of assessment, areas of observed nonconsensus were discussed. When feasible, revised statements were proposed to undergo additional assessment for possible consensus, using the same rating system as above. Two rounds of surveys were performed, with newly proposed statements in the second round based on further understanding of panelists' viewpoints. A summary of recommendations can be found in Table 1.

## 4 | PREPROCEDURAL EVALUATION

### 4.1 | Benign thyroid nodules

Several disease and patient factors must be considered when evaluating a patient for RFA and other US-guided ablation procedures. For benign thyroid nodules, size, as determined by US measurement, represents the most objective criterion to determine candidacy. However, similarly sized nodules cause different degrees of symptoms that vary significantly between patients. Factors such as body mass index and neck circumference, as well as precise location within the thyroid, influence how symptomatic a patient becomes. Isthmus nodules, for example, tend to cause earlier and more prominent cosmetic disturbances. For this reason, determining appropriate size requirements for ablation is challenging. Prior guidelines have suggested a minimum diameter of 20–30 mm with continued growth on US.<sup>2,3,51</sup> Given the difficulty in defining objective size criteria, the presence of compressive symptoms and cosmetic concerns are considered appropriate clinical indications to warrant intervention. For instance, a nodule that is the clear source of clinical symptoms remains an appropriate target for RFA despite limited size. Symptom score may be assessed on a visual analogue scale of 0 (*no symptoms*) to 10 (*maximal symptoms*). Cosmetic score may be determined by the physician on a scale of 1–4 as has been described previously.<sup>2</sup> The Short Form Health Survey (SF-36) provides generic assessment of quality of life measures.<sup>52</sup> More specifically, the Thyroid-Related Patient-Reported Outcome (ThyPRO) is a well-validated 85-item tool for evaluating thyroid-related quality of life; a recently developed abbreviated version (ThyPRO-39) is also applicable in this clinical setting.<sup>53</sup>

Functional thyroid nodules may be targeted with RFA.<sup>54,55</sup> It should be noted, however, that resolution of hyperthyroidism is less predictable than after radioactive iodine (RAI) or extirpative surgery, with reports for success of RFA ranging from 24% to 72%.<sup>54,56–58</sup> Because efficacy is associated with nodule volume reduction of 80% or greater, RFA is best suited for patients with small ( $\leq 3$  cm) nodules and contraindications to RAI or surgery.<sup>3,59</sup> Scintigraphy is recommended to confirm the presence of an autonomously functional nodule, as ablation is less effective in toxic multinodular goiter or Graves' disease.<sup>3,60</sup> TSH should be documented prior to ablation for both functional and nonfunctional nodules; T3 and free T4 should be measured whenever TSH falls outside the normal range.

TABLE 1 Summary of recommendations

Recommendation 1	US-guided ablation procedures may be used as a first-line alternative to surgery for patients with benign thyroid nodules contributing to compressive and/or cosmetic symptoms
Recommendation 2	Although less efficacious than surgery or RAI in normalizing thyroid function, thermal ablation procedures can be a safe therapeutic alternative in patients with an autonomously functional thyroid nodule and contraindications to first-line techniques
Recommendation 3a	US-guided ablation procedures may be considered in patients with suitable primary papillary microcarcinoma who are unfit for surgery or decline surgery or active surveillance
Recommendation 3b	US-guided ablation procedures may be considered in patients with suitable recurrent papillary thyroid carcinoma who are unfit for surgery or decline surgery or active surveillance
Recommendation 3c	Preprocedural biochemical and imaging assessment aid in determining curative versus palliative treatment intent for treatment of recurrent papillary thyroid carcinoma
Recommendation 4a	Subjective voice assessment should be undertaken prior to performance of US-guided ablation procedures in any candidate
Recommendation 4b*	Patients with voice impairment or relevant prior surgical history warrant a laryngeal evaluation and assessment of vocal fold mobility
Recommendation 4c	Laryngeal exam should be performed prior to ablation on the contralateral side after ipsilateral ablation
Recommendation 5a	Prior to pursuing US-guided ablation procedures, complete radiographic, biochemical, medical, and symptomatic evaluation should be performed and may be facilitated by completion of a checklist
Recommendation 5b	Prior to pursuing US-guided ablation procedures, discussion should be held with the patient regarding expected outcome(s) and potential risks
Recommendation 6**	When patient comorbidities and disposition permit, performance of US-guided ablation procedures under local anesthesia allows for monitoring of periprocedural complications
Recommendation 7	Hydrodissection creates distance between the target lesion and vital structures, thereby minimizing patient discomfort and reducing unintended thermal spread
Recommendation 8a	In performance of RFA, utilization of the moving shot technique via the transisthmic approach and delivery of energy only when the needle tip is visualized by US is paramount to effective ablation
Recommendation 8b	The moving shot technique via the transisthmic approach minimizes inadvertent thermal injury to surrounding critical structures
Recommendation 9	Continuous patient vital sign monitoring is not universally required for all ablation techniques; however, established guidelines for procedural sedation in adults should be followed if sedation is administered
Recommendation 10	Immediate clinical and ultrasonographic assessment of acute complications following thermal ablation is required
Recommendation 11a	Subjective voice assessment should be undertaken by the treating physician following ablation in any candidate
Recommendation 11b	Changes in voice compared with the preoperative status reported by the patient or detected by the physician require laryngeal evaluation with assessment of vocal cord mobility
Recommendation 12	Careful documentation of both objective and subjective metrics before treatment and during the follow up period is important to establish treatment effectiveness and to set realistic expectations
Recommendation 13a	Following thermal ablation for benign nodules, primary objective measures of efficacy include ultrasonographic measurement of volume reduction and preservation or normalization of thyroid function
Recommendation 13b	Patient-reported outcomes, including validated symptom, cosmetic, and quality of life instruments may be used to determine efficacy
Recommendation 13c	Repeat ablation of a benign nodule can be considered for remnant nodular tissue contributing to unresolved symptomatic or cosmetic concerns
Recommendation 13d	Retreatment for persistent hyperthyroidism may be performed
Recommendation 14	Following thermal ablation for recurrent malignancy, ultrasonographic determination of tumor volume, assessment of locoregional disease status, and serum Tg/TgAb are performed to evaluate treatment response
Recommendation 15	In the setting of primary malignancy, sonographic volume reduction or complete resolution of the malignant lesion, along with long-term assessment of disease progression, are necessary to determine oncologic effect

(Continues)

TABLE 1 (Continued)

Recommendation 16	Assiduous recording of complications resulting from thermal ablation is recommended in order to accurately inform practitioners and patients about the safety of these procedures
Recommendation 17a	Prior to performing any US-guided thermal ablation procedure, advanced training in and facility with US of the thyroid and neck are essential
Recommendation 17b	Proficiency with US-guided fine needle aspiration biopsies of thyroid nodules is recommended for performance of US-guided ablation procedures
Recommendation 17c	The provider should receive specific instruction on the chosen ablation technique, with the opportunity to practice on a phantom model and observe cases
Recommendation 17d	Optimal practice involves one's initial cases being supervised by a physician experienced in US-guided ablation procedures
Recommendation 18	Physicians performing US-guided thyroid ablation who do not provide longitudinal patient care should communicate and facilitate long-term follow-up with a care team specializing in management of nodular thyroid disease
	*Indicates statement did not reach consensus among author voting panel. Seven of 39 voting authors voted "neutral" or "disagree"
	**Indicates statement was borderline for meeting consensus among author voting panel. Three of 39 voting authors voted "neutral" or "disagree"

In accordance with previous guidelines, a benign cytologic diagnosis must be confirmed via two ultrasound-guided fine needle aspiration biopsies (FNAB) or core needle biopsies (CNB) prior to ablation of a benign thyroid nodule.<sup>2,3,51,61</sup> When ultrasonographic features are highly specific for benignity, as in spongiform and purely cystic nodules, the second FNAB may be omitted. FNAB is not a prerequisite in functional nodules. Caution should be taken in ablating nodules with suspicious ultrasound features so as not to overlook and delay treatment of a malignant lesion. Retrosternal extension should be carefully assessed with cross-sectional imaging, and, if significant, renders the patient unsuitable for ablation.

## 4.2 | Cytologically indeterminate thyroid nodules

There is very little literature regarding treatment of cytologically indeterminate nodules with RFA. A primary objective of surgery in the management of these nodules is removal and definitive diagnosis. RFA does not facilitate diagnosis to any degree, nor does it remove the nodule. Furthermore, it does not prevent metastasis if a nodule is indeed malignant, and may confound future attempts at diagnosis. As such, it is presumed that success in the management of indeterminate nodules would be radiographic elimination of the target lesion. However, incomplete treatment with RFA has led to tumor progression in other organ systems and tumor types.<sup>62–65</sup> Therefore, management of indeterminate nodules with RFA is not recommended at this time.<sup>66</sup>

## 4.3 | Malignant disease

Surgery is the standard treatment for patients with primary and recurrent well-differentiated thyroid cancer, although RFA may be an option when surgery is contraindicated or declined. At present, the role of RFA in the treatment of thyroid malignancy remains an area of active debate. RFA has been utilized in the setting of recurrent papillary thyroid carcinoma<sup>2,51</sup> and has shown promising results in papillary thyroid microcarcinoma (PTMC).<sup>67–69</sup> Prior to proceeding with RFA of metastatic lesions, malignancy should be confirmed via FNAB or CNB with thyroglobulin washout as needed. The serum thyroglobulin and thyroglobulin antibody levels are also determined to assess treatment response during extended follow-up.

An important distinction in the ablation of recurrent malignancy is the treatment intent. For a curative strategy, the number of lesions must be limited ( $\leq 3$  per patient), confined to the neck, and with maximum tumor diameter below 1.5–2 cm.<sup>48,70,71</sup> If the strategy is palliative, larger tumors can be targeted with RFA when it is judged that size reduction would reduce symptoms and improve quality of life due to relationship with critical structures. In either case, ultrasonographic assessment of the target nodule(s) is required to determine size, vascularity, and proximity to adjacent structures. In patients deemed to be at risk for more extensive locoregional or distant metastatic disease, cross-sectional and/or functional imaging may be required to detect metastatic disease and help define the treatment purpose. These steps are summarized in Table 2.



**TABLE 2** Preablation evaluation of recurrent thyroid malignancy

Thyroid carcinoma recurrence	
Malignancy confirmation	
FNAB	
Cytology	
Thyroglobulin washout	
Core needle biopsy <sup>a</sup>	
Recurrence site and size evaluation	
Neck ultrasound	
Axial imaging (CT or MRI)	
Functional images ( <sup>131</sup> I Scan; PET/CT)	
Biochemical evaluation	
Thyroglobulin level	
Thyroglobulin antibody level	
Serum TSH	

<sup>a</sup>Can be considered if FNAB does not yield sufficient information.

RFA is currently not considered first-line for treatment of primary thyroid cancer. Although mounting data suggest efficacy, indications for treatment in this setting are increasingly discussed.<sup>72</sup> At present, candidate primary tumors should demonstrate the following characteristics: (1) unifocal microcarcinoma confined to the thyroid gland, without evidence of extrathyroidal extension or capsular contact, (2) cytologic confirmation of papillary thyroid cancer without aggressive subtype, (3) no evidence of metastatic lymphadenopathy, (4) high-risk, ineligible for, or declines surgery.<sup>48,71,73</sup>

#### 4.4 | Ultrasound evaluation and considerations

Preprocedural ultrasound is critical in evaluating characteristics of the target lesion in both benign and malignant disease. Preoperative nodule or tumor dimensions and volume are established to compare with subsequent follow-up exams. The proportion of solid and cystic components is assessed to determine the optimal ablation technique.<sup>74,75</sup> Vascularity is additionally observed. Examples of candidate lesions and corresponding ablative techniques are shown in Figure 1.

The preoperative ultrasound is also an opportunity to identify anatomic landmarks for a safe ablation.<sup>76</sup> Of particular interest for thyroid nodules and central neck disease is the tracheoesophageal groove, or so-called “danger triangle,” where the recurrent laryngeal nerve

(RLN) is not visible but is expected to be present and is vulnerable to thermal injury (Figure 2). Anterior jugular veins are sought out and avoided to reduce risk of hematoma formation. Relevant to both benign lesions in the thyroid gland as well as recurrent malignancy in the central or lateral neck, the vagus nerve must be located in the carotid sheath. Although not amenable to mapping sonographically, the sympathetic chain is also considered in its course deep and lateral to the carotid artery. With lateral neck disease, the operator must be additionally mindful of the potential locations of the spinal accessory nerve, brachial plexus, and other neural structures.

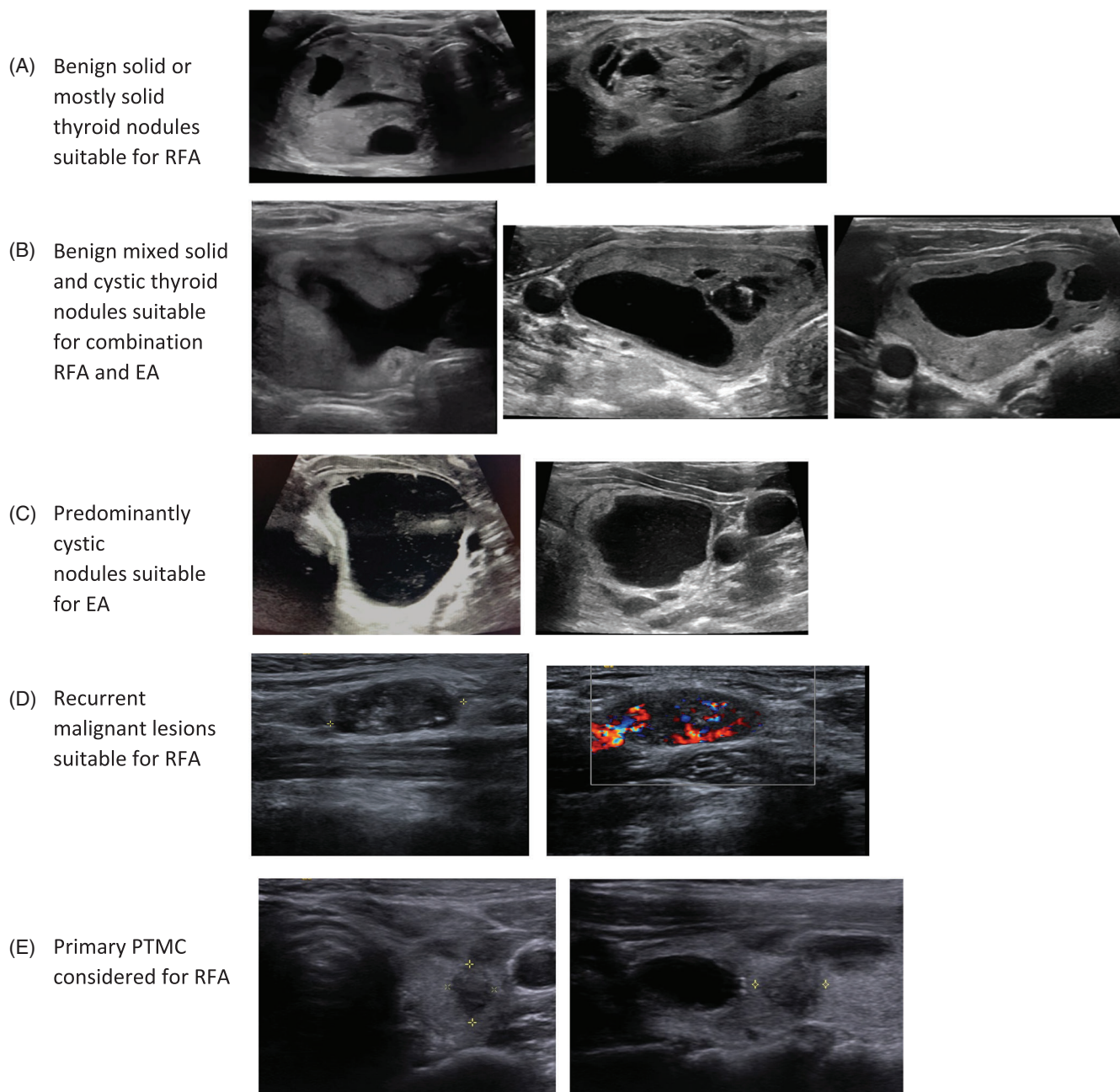
#### 4.5 | Voice and laryngeal assessment

A voice assessment is required prior to proceeding with ablation and is a documented component of the physical examination.<sup>77,78</sup> At a minimum, the patient is asked whether she/he considers her/his voice abnormal or has noticed changes in pitch, loudness, quality, or endurance.<sup>79</sup> Although not routine, additional investigation with validated instruments<sup>80,81</sup> may be considered to determine the presence and degree of impairment.

Most importantly, voice abnormality requires examination of the larynx to assess vocal fold mobility. Laryngeal visualization via transnasal or transoral fiberoptic or mirror laryngoscopy is the gold standard exam. Adequate assessment of vocal fold mobility may be obtained using laryngeal ultrasound in select patients with favorable anatomy.<sup>82</sup> Examination of vocal fold mobility is also indicated if the patient has undergone prior thyroid or neck surgery.<sup>82</sup> Voice is a poor predictor of objective vocal fold function, and thus voice assessment alone is not a substitute for laryngeal examination in this population at higher risk for occult dysfunction.<sup>79</sup>

#### 4.6 | Informed consent

Informed consent is another essential component of the preprocedural process. It is the responsibility of the physician to set clear expectations during and following ablation. Patients may experience some degree of discomfort, not only in the neck, but in the ears, jaw, teeth, back, or chest. The risks of RFA are not dissimilar to those of open surgery and are reviewed in greater detail in the “Complications” section. A sample informed consent template for RFA can be found in Figure S1, Supporting Information.

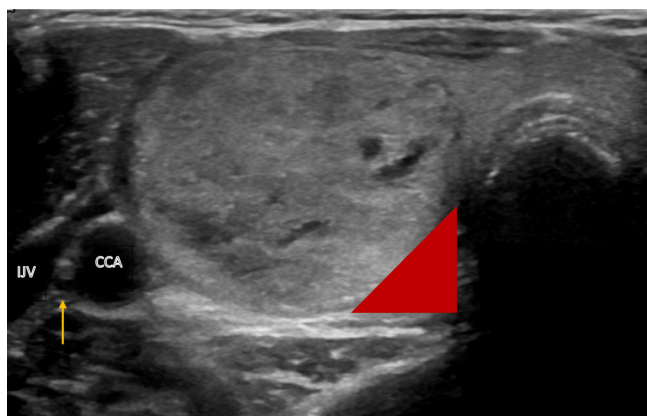


**FIGURE 1** Ultrasonographic examples and recommended ablative techniques. Sonographic patterns of candidate lesions for ablation. (A) Examples of benign nodules with primarily solid or spongiform patterns that would be amenable to radiofrequency ablation. (B) Examples of mixed solid and cystic nodules with a significant cystic component best addressed with a combination of ethanol ablation (EA) for the cystic portion and RFA for the solid portion. (C) Examples of entirely or nearly entirely cystic nodules likely to be sufficiently reduced by ethanol ablation (EA) alone. (D) Examples of isolated recurrent papillary thyroid carcinoma in lateral neck lymph nodes, amenable to RFA. (E) Example of a unifocal papillary thyroid microcarcinoma without adverse features or radiographic evidence of metastatic disease, amenable to RFA

#### 4.7 | General assessment of procedural fitness

Evaluation of the patient's overall medical status and constitution is warranted for appropriate preparation, counseling, and choice of procedural venue. The physician should

inquire about medical conditions and associated medications, prior surgical history, and pregnancy status. In particular, significant cardiopulmonary comorbidities, especially presence of a pacemaker, implantable defibrillator, or arrhythmia, may encourage the physician to pursue treatment under continuous monitoring. Patient factors that warrant



**FIGURE 2** Position of danger triangle and vagus nerve. The danger triangle, or anticipated location of the recurrent laryngeal nerve, is indicated by the red triangle. Note that, on the right side, this triangle has a longer base moving inferiorly because of the oblique orientation of the nerve. The vagus nerve (yellow arrow) appears as a round, hypoechoic structure between the internal jugular vein (IJV) and common carotid artery (CCA). In some patients the vagus nerve courses medially within the carotid sheath in close approximation to the thyroid. Furthermore, the course of the vagus nerve can be variable with respect to the vessels as the nerve descends in the neck

consideration for deep sedation instead of local anesthesia include extreme anxiety, chronic opiate dependence, fibromyalgia, cognitive disabilities, or prior poor tolerance to procedures (i.e., FNAB).<sup>83</sup>

## 4.8 | Management of anticoagulation

The introduction of new oral anticoagulants in the past decade has increased the complexity of preprocedural anticoagulation management. Optimal strategies must weigh the procedural bleeding risk, the pharmacokinetics of the anticoagulant, and the patient's risk for a thromboembolic event. In general, antiplatelet agents such as aspirin or clopidogrel are stopped 7–10 days before RFA. Warfarin is held for 5 days preprocedurally. The direct oral anticoagulants, which include dabigatran, rivaroxaban, apixaban, and edoxaban, are held for 24–36 hours.<sup>84</sup> All agents can be safely resumed 24 hours after completing the procedure.

A checklist summarizing the above preprocedural evaluation steps can be found in Figure S2.

**Recommendation 1:** US-guided ablation procedures may be used as a first-line alternative to surgery for patients with benign thyroid nodules contributing to compressive and/or cosmetic symptoms.

**Recommendation 2:** Although less efficacious than surgery or RAI in normalizing thyroid function,

thermal ablation procedures can be a safe therapeutic alternative in patients with an autonomously functional thyroid nodule and contraindications to first-line techniques.

**Recommendation 3a:** US-guided ablation procedures may be considered in patients with suitable primary papillary microcarcinoma who are unfit for surgery or decline surgery or active surveillance.

**Recommendation 3b:** US-guided ablation procedures may be considered in patients with suitable recurrent papillary thyroid carcinoma who are unfit for surgery or decline surgery or active surveillance.

**Recommendation 3c:** Preprocedural biochemical and imaging assessment aid in determining curative versus palliative treatment intent for treatment of recurrent papillary thyroid carcinoma.

**Recommendation 4a:** Subjective voice assessment should be undertaken prior to performance of US-guided ablation procedures in any candidate.

**Recommendation 4b:** Patients with voice impairment or relevant prior surgical history warrant a laryngeal evaluation and assessment of vocal fold mobility.

**Recommendation 4c\*:** Laryngeal exam should be performed prior to ablation on the contralateral side after ipsilateral ablation.

**Recommendation 5a:** Prior to pursuing US-guided ablation procedures, complete radiographic, biochemical, medical, and symptomatic evaluation should be performed and may be facilitated by completion of a checklist, as can be found in Figure S2.

**Recommendation 5b:** Prior to pursuing US-guided ablation procedures, discussion should be held with the patient regarding expected outcome(s) and potential risks.

Asterisk (\*) indicates statement did not reach consensus among author voting panel. Seven of 39 voting authors voted “neutral” or “disagree.”

## 5 | TECHNIQUE

### 5.1 | Radiofrequency ablation

Although the ensuing description of procedural setup is specific to the performance of RFA, this component is similar for LTA, HIFU, and MWA. The differing technical details for these ablation technologies are reviewed separately below. The venue in which ablation is performed will vary according to the preference of the proceduralist and anticipated comfort and safety of the patient.

Prior to procedure check-in, the patient should avoid a heavy meal and have a companion accompany them to

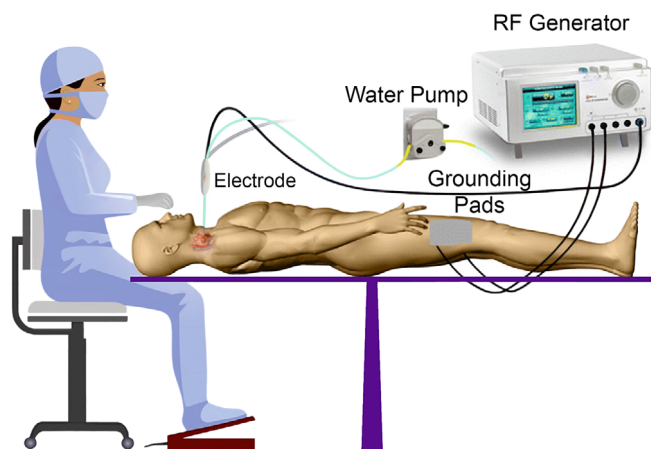


FIGURE 3 Positioning and set up for RFA procedure

and from the appointment. As shown in Figure 3, the patient lies supine with gentle neck extension, while the operator is positioned at the head of the table. It is important to understand that the US images will, therefore, be inverted on the screen. Grounding pads are placed distal to the neck, usually on both anterior thighs, after confirmation of no metal on the body (e.g., jewelry, piercings, hearing aids, clothing hooks, or wires), to avoid conduction-related injuries. The patient's eyes may be covered to prevent inadvertent injury. The neck skin should be cleansed and the field draped. For more anxious patients, a mild sedative (e.g., alprazolam, 0.5–1 mg PO) may be helpful to maintain relaxation during the procedure.<sup>2,3</sup> Measurement of preprocedure and postprocedure vital signs is recommended. Monitoring of blood pressure, heart rate, and pulse oximetry may be considered, especially if administering a sedative. The same degree of monitoring is not universally required for all ablation procedures and should be adjusted as indicated by established guidelines for procedural sedation in adults.<sup>85</sup> It is advisable to have an emergency “crash cart” and oxygen available in the rare instance where cardiac arrhythmia develops.

Three basic technical components for RFA of thyroid nodules comprise the procedure: local anesthesia, the transisthmic approach, and the moving-shot technique.<sup>86,87</sup> To prevent pain during RFA, it is important to inject sufficient local anesthetic (e.g., 1% lidocaine) into the skin puncture site and around the thyroid capsule.<sup>88</sup> Sensory nerves are present in the skin at the thyroid capsule, but not within the gland. Local anesthetic is first administered at the intended site(s) of RFA electrode insertion in the anterior neck based on baseline ultrasound assessment of trajectory (ies) required to access the target nodule. Perithyroidal lidocaine injection is then performed. The infiltrated lidocaine appears as an anechoic band separating the thyroid gland and overlying sternothyroid muscle. The total amount of

lidocaine that can be safely administered is calculated based on patient's weight and renal function.<sup>89,90</sup>

The additional purpose of local anesthetic infiltration is hydrodissection, which achieves separation of the thyroid from adjacent vulnerable structures and creates a liquid barrier or heat sink. Hydrodissection with lidocaine or complementary 5% dextrose in water is advantageous since it does not conduct electricity and provides a thermal barrier when it surrounds the target organ.<sup>91,92</sup> Under local anesthesia, complications such as voice change and ptosis can be monitored. In contrast, general anesthesia may delay the detection of such complications during ablation.<sup>93</sup> Patients are asked to communicate any onset of neck pain. This usually indicates heating of the thyroid capsule and thermal propagation outside of the thyroid gland. Discontinuation of treatment followed by administration of more local anesthetic and/or repositioning of the RFA electrode is required. Nonverbal patient communication may be utilized to avoid inadvertent injury resulting from displacement of the electrode with speaking, which should be avoided while the electrode tip is active.

The transisthmic approach refers to the insertion of the electrode via the isthmus, in a medial to lateral direction, for treatment of a nodule in either the right or left thyroid lobe.<sup>94,95</sup> The transisthmic approach allows the operator to constantly monitor the association between the electrode, target nodule, and vicinity of the RLN, which is known to be situated in the “danger triangle”, as in Figure 2. The normal isthmic parenchyma between the target nodule and the electrode insertion site prevents the leakage of hot ablated fluid to the perithyroidal area, which might otherwise cause pain or thermal injury. The transisthmic approach allows the electrode position to remain stable even when a patient speaks, swallows, or coughs, preventing possible injury. RFA of actual isthmic nodules may require a more paramedian approach.

Unlike RFA of other organs such as the liver, where the active tip of the electrode is fixed to the center of the target tumor, a moving shot technique is recommended for treating thyroid nodules. Since thyroid nodules are often elliptical and exophytic from the thyroid gland, they are difficult to ablate using a fixed technique, which may undertreat or overtreat the nodule periphery and adjacent tissue. Instead, it is advantageous to treat a thyroid nodule by dividing it into multiple small ablation units which are individually treated.<sup>14</sup> The procedure should begin by ablating unit-by-unit, from the deepest to the most superficial portion of the nodule, ablating as the electrode tip is withdrawn. Ablation should be suspended when the electrode moves in a forward direction to be repositioned.<sup>96</sup> Power settings are chosen at the discretion of the operator but start

conservatively around 45 W and may be increased to 70 W or more according to patient tolerance to increase ablative efficiency. Since heat and therefore injury can extend for a distance of 1–3 mm beyond the electrode tip, advancement of the electrode must take into account the size of the active tip, level of power, and proximity to vital structures.<sup>75</sup> The location of the electrode tip should be continuously monitored via real time US during the entirety of the procedure. For ablation of a benign thyroid nodule, the operator may expect a total of 15–50 kJ of energy to be applied depending on the nodule size and ablation length.

Vascular ablation techniques have been introduced to minimize marginal regrowth.<sup>75</sup> The artery-first ablation technique can be used for hypervascular nodules with a prominent feeding artery.<sup>97</sup> Ablating the artery first reduces edema and the heat-sink effect in hypervascular tumors, while also limiting risk of hemorrhage, which can interfere with thermal conduction. Doppler US is useful for the identification of the nodule's main arterial supply.

The marginal venous ablation technique is directed at marginal draining veins which contribute to the heat sink effect and prevent complete ablation of the margin of the target nodule.<sup>75</sup> This technique is useful for marginal veins at the anterior portion of thyroid nodules, which have a sufficiently large safety margin for ablation. This technique may also be helpful in preventing recurrent nodule growth.<sup>98</sup>

In treating functional nodules and recurrent nodal disease, a more extensive margin is necessary for complete eradication.<sup>88,99</sup> For treatment of recurrent thyroid cancers, the moving-shot technique should include the soft tissue surrounding the recurrent tumors.<sup>100</sup> The position of tumor relative to normal neck structures including the RLN, esophagus, or trachea must be assessed prior to ablation.<sup>96</sup> The hydrodissection technique is useful for separating a tumor from these critical structures.<sup>91,92,101</sup> An electrode with a small active tip (i.e., 0.38 or 0.5 cm) is effective and safest for treating small primary and/or recurrent tumors.<sup>88</sup>

## 5.2 | Technique/equipment considerations

As with any procedure, utilization of the appropriate equipment is necessary to achieve optimal outcomes in thyroid RFA. The electrodes employed for thyroid RFA have been specifically designed for this function. Electrodes with varying tip sizes (e.g., 5, 7, and 10 mm) are available. Choice of tip size should be determined by the

dimensions of the nodule requiring treatment and the degree of precision required. Nodules in more high-risk locations or abutting critical structures call for the use of smaller electrodes. For larger nodules (>4 cm), use of the 10 mm electrode can be considered in order to reduce ablation time. The 5 mm electrode is reserved for smaller nodules and those requiring a high degree of control of the treatment area. Electrodes with adjustable tip sizes have been developed, permitting multiple functions in a single device.<sup>102</sup>

Currently, monopolar electrodes are used in the majority of thyroid RFA cases, although bipolar electrodes are also now available. Bipolar probes, in which current only passes between the electrodes at the tip of the device, deliver more focused energy. Use of bipolar electrodes in patients who are pregnant or those with implanted cardiac electrical devices may be safer.<sup>88</sup> Bipolar electrodes have not yet received FDA approval in the United States but are in clinical use in other geographic regions, including in Asia and Europe.

Additional innovations have been introduced to further increase the safety profile of thyroid nodule RFA. Unidirectional ablation electrodes are insulated in a manner to create a more focused, narrower ablation zone and may be considered for cases in which the ablation target directly abuts a critical structure.<sup>88</sup> Virtual needle tracking systems have also been developed as a means to facilitate monitoring of the electrode tip. These are more useful for a fixed ablation rather than moving shot technique,<sup>103</sup> although may offer benefit for clinicians early in their RFA experience.

## 5.3 | Laser ablation

In LTA, one or multiple 21-gauge introducer needles are placed 10 mm apart into the thyroid nodule. Optical fibers of 300  $\mu\text{m}$  diameter are inserted through the sheath of the needle, then the needle is retracted to allow at least 5 mm of bare fiber to come into direct contact with the thyroid tissue. After all laser safety checks are completed, the energy is delivered simultaneously, commonly via Nd:YAG laser. Typically, a mean power of 2–4 W is applied for each diode for a total energy of 1200–1800 J for every illumination. During the laser firing, a highly echogenic region will develop in real-time from the heating and vaporization. The fiber(s) can be pulled back incrementally by 1–1.5 cm to allow additional doses of energy to be delivered until the entire nodule has been illuminated. The number of fibers, repeat deliveries after pullbacks, and total amount of energy used are tailored to the nodule volume and shape.<sup>12,74,104–107</sup>

## 5.4 | Microwave ablation

The microwave system consists of a generator and an internally cooled shaft antenna. The generator operates at a frequency of 2450 MHz, with power up to 100 W. The antenna is 16-gauge, 10 cm in total length, with a 3-mm active tip. After a 1–2 mm incision is made in the skin, the antenna is inserted into the isthmus and placed into the target nodule along its longest axis. The target nodule is treated in smaller units by using the moving-shot technique. The ablation power is commonly set from 20 to 50 W. The procedure is terminated once the entire nodule is hyperechoic.<sup>108–112</sup>

## 5.5 | High-intensity focused ultrasound

The HIFU device consists of an energy generator, a probe (or transducer), a monitor, and a cooling device. The probe operates on both an ultrasound image-guiding system and a therapeutic HIFU transducer system, where the former is placed in the middle of the probe so that the center of the image captures the focal point of treatment. The probe is positioned on the skin to view the targeted nodule. Treatment and nontreatment areas are then defined by the HIFU device, with each ablation site measuring 7.3–9 mm by 1.8–5 mm. The operator can also contour the target manually on the monitor in the sagittal and transverse planes. A HIFU pulse is then delivered for 4–8 s, followed by a 15–50 s cooling time. The transducer can emit frequencies of 3 MHz of pulses up to 125–160 W of power. The first pulse is delivered at the center of the nodule to allow for initial assessments of white hyperechoic marks. Each pulse is capable of inducing temperatures between 60°C and 80°C in an ellipsoid shape with a diameter of 2 mm and length of 9 mm. A laser-based movement detector interrupts delivery of the US pulse in the event of neck movement during ablation. Cooling of the skin is performed by circulating a 10°C liquid through a balloon at the probe.<sup>113–116</sup>

## 5.6 | Ethanol ablation

Like thermal ablation, ethanol ablation is generally performed in an outpatient setting, most commonly for predominantly cystic nodules. The patient is placed supine in mild neck extension. The skin is prepped and local anesthetic (1%–2% lidocaine) may be injected at the skin puncture site.<sup>1</sup> Under ultrasound guidance, a single 16–25 G needle is inserted into the center of the cystic area (gauge depends on the viscosity of cyst content). A transisthmic approach is recommended to help stabilize

the position of the needle tip and prevent ethanol leakage when the patient swallows or speaks. Cyst contents are aspirated as much as possible, with care taken to keep the needle tip within the middle of the cyst and avoid inadvertent puncture of the cyst wall. Sterile saline irrigation can be used to facilitate removal of residual debris, colloid, and/or dilute high viscosity cyst fluid. Large bore needles, repeated ethanol injection over an interval period, or even large pigtail catheters connected to a suction pump have all been used as adjuncts for highly viscous content.<sup>117–119</sup>

Once all cyst contents have been satisfactorily removed, an appropriate amount of 95%–99% ethanol is slowly injected into the cystic space. Although it is recommended that the total amount of ethanol should be tailored according to the size and internal content of the lesion and patient tolerance, there is no consensus for an absolute amount, and larger amounts of up to 50% of aspirate volume can be considered if re-aspirated after a short interval.<sup>120–124</sup> A minimum retention time of 2 min was found to be sufficient by Kim et al. for ethanol to react with the cells.<sup>117</sup> If pain is noted during the procedure, the ethanol injection should be stopped and there should be evaluation for a possible perithyroidal leak.

There is no expert consensus on whether ethanol should be fully aspirated after instillation. Several studies have suggested there is no difference in complication or success rates between groups in which ethanol was retained or aspirated after injection,<sup>125,126</sup> but others have suggested that complete removal of ethanol after a short retention time decreases rates of ethanol leakage and may increase patient satisfaction after the procedure because of the immediate reduction in the size of the nodule.<sup>117,127</sup> Therefore, the amount of retained ethanol after injection is left to the operator's discretion.

Percutaneous ethanol ablation may be used to treat recurrent lymph node disease.<sup>128–132</sup> For solid lymph nodes, a 25-gauge needle is attached to a tuberculin syringe containing 95%–100% ethanol. Typically, the needle is inserted into the deepest portion of the node and a small amount of ethanol (0.05–0.1 mL) is injected, causing that portion of the node to become intensely echogenic. After the “hyperechoic bubble” fades in a few minutes, the needle is once more visualized and repositioned within the next zone of the node, injected, and repeated until the entire lymph node has been adequately treated. Care is taken to inject small amounts of ethanol in each site to prevent diffusion of ethanol along the needle track into surrounding cervical soft tissues. Multiple sessions may be necessary to treat the entire node. Any residual color perfusion within the node suggests residual vascularity and requires re-treatment. For predominantly cystic lymph nodes, a technique similar to

that used for cystic nodules can be used, except that all residual ethanol is fully aspirated at the end of the procedure.<sup>1</sup>

Recommendation 6<sup>\*\*</sup>: When patient comorbidities and disposition permit, performance of US-guided ablation procedures under local anesthesia allows for monitoring of periprocedural complications.

Recommendation 7: Hydrodissection creates distance between the target lesion and vital structures, thereby minimizing patient discomfort and reducing unintended thermal spread.

Recommendation 8a: In performance of RFA, utilization of the moving shot technique via the transisthmic approach and delivery of energy only when the needle tip is visualized by US is paramount to effective ablation.

Recommendation 8b: The moving shot technique via the transisthmic approach minimizes inadvertent thermal injury to surrounding critical structures.

Recommendation 9: Continuous patient vital sign monitoring is not universally required for all ablation techniques; however, established guidelines for procedural sedation in adults should be followed if sedation is administered.

Asterisks (<sup>\*\*</sup>) indicates statement was borderline for meeting consensus among author voting panel. Three of 39 voting authors voted “neutral” or “disagree.”

## 6 | POSTPROCEDURAL CONSIDERATIONS

### 6.1 | Acute postprocedure management

Clinical and ultrasound evaluation should be performed upon completion of the RFA procedure to assess the area of ablation and detect potential early adverse effects, as well as to confirm appropriate response in the target lesion. The treated area often appears as a mildly hypoechoic and heterogeneous zone, with scattered hyperchoic spots due to tissue dehydration.<sup>3</sup> Color Doppler mapping improves definition of the treated area, which appears as devoid of vascular signals. If available, contrast-enhanced US can provide a more accurate assessment of the loss of small vessel signals and better depict the incompletely ablated peripheral areas, which should be treated if safe and indicated.<sup>6</sup>

Following treatment, application of an ice pack provides comfort and reduces local edema and discomfort. Anti-inflammatory medication (e.g., ibuprofen) may be given orally, followed by non-NSAID analgesics (e.g., acetaminophen) during the following 24 h. Routine use of steroids and antibiotics is not indicated. Patients should be observed for 30–60 min prior to discharge. Any patient with difficulty swallowing,

speaking, breathing, or hemodynamic abnormalities should be admitted for observation. Postprocedure instructions should be provided, with specific advice regarding symptoms that warrant prompt clinical attention. These include severe or worsening pain, local swelling and erythema, fever, voice change, difficulty swallowing, or breathing.<sup>3</sup>

Voice evaluation is a critical component of establishing procedural safety and monitoring one's own complication rate. Following completion of treatment, the voice is re-assessed subjectively by the patient and physician, as was done preprocedurally.<sup>79</sup> Any changes in vocal quality raise concern for RLN injury, whether via thermal propagation or compression from nodule expansion or hematoma. In this scenario, direct visualization of vocal fold motion via laryngoscopy, either by the operator or a consultative service, must be performed.<sup>82</sup> Transcutaneous US also permits laryngeal assessment, and is perhaps more efficient in the context of an US-guided ablation. However, adequate visualization is impacted by age and sex, and subtle motion abnormalities may elude detection on ultrasound.<sup>133,134</sup> For the patient in whom bilateral ablation is being performed, confirmation of intact vocal fold mobility by direct visualization is recommended between sides in order to prevent the possible complication of bilateral vocal fold paralysis. A postprocedural checklist for thyroid ablation can be found in Figure S3.

### 6.2 | Extended follow-up

Following RFA, clinical, radiographic, and biochemical monitoring are undertaken at regular intervals to assess treatment response and thyroid function. A suggested timeline with follow up metrics can be accessed Table S1.

For benign nonfunctional nodules, complete thyroid function tests as well as thyroid and neck US are performed at follow-up.<sup>2–4</sup> At 12 months, the near maximum expected size reduction has typically been achieved,<sup>135</sup> and thyroid function tests are unnecessary beyond this time. Nodule-related symptom and cosmetic scores should be documented using consistent validated metrics, as discussed previously. Long-term follow-up with US is recommended in all cases, as 5%–24% of treated nodules have been shown to regrow between 3 and 5 years, and may require repeat ablation or surgery.<sup>136–138</sup> Such decisions are made on the basis of remnant nodular volume and vascularity on ultrasound, as well as patient satisfaction and symptomatology. Cross-sectional imaging is generally not warranted unless following response to a nodule with substernal extension.

Because of the potential for more rapid change in hormone status after ablation of an autonomously functional nodule, thyroid function is evaluated frequently

postprocedurally, and at least annually thereafter.<sup>2,54,139</sup> As with nonfunctional nodules, US is also performed at each follow-up. Finally, consideration is given to repeating scintigraphy to help assess the degree of functional response. Repeat ablation or alternative therapeutic interventions may be required for persistent hyperthyroidism.

After ablation of recurrent thyroid malignancy, attention on ultrasonographic follow-up is directed to volume reduction and intratumoral vascularity to determine response.<sup>70</sup> Thyroglobulin (Tg) and antithyroglobulin antibody (TgAb) are assessed in conjunction. Cross-sectional imaging is optional to further assess treatment response or to identify new areas of concern. After the first year, surveillance can be resumed according to the schedule indicated by tumor status.

It should be noted that the post-treatment nodule takes on ultrasonographic characteristics that might otherwise be interpreted as concerning, including a hypo-echoic background with internal echogenic foci.<sup>94,95</sup> While FNAB of ablated nodules does not indicate malignant transformation,<sup>140</sup> the interpreting physician must be aware of these changes in appearance. Ideally, the provider performing the ablation will also continue US surveillance to ensure appropriate interpretation and avoid undue suspicion and biopsy.

Recommendation 10: Immediate clinical and ultrasonographic assessment of acute complications following thermal ablation is required.

Recommendation 11a: Subjective voice assessment should be undertaken by the treating physician following ablation in any candidate.

Recommendation 11b: Changes in voice compared with the preoperative status reported by the patient or detected by the physician require laryngeal evaluation with assessment of vocal fold mobility.

## 7 | EFFICACY/OUTCOMES

### 7.1 | Measures of success

#### 7.1.1 | Benign disease

RFA may be offered as an alternative to surgical removal for cytologically benign thyroid nodules in appropriate patients.<sup>2</sup> Whereas surgical success is objectively measured, success after RFA is more likely to be defined by predetermined expectations agreed upon between the treating physician and patient.<sup>86</sup> Importantly, in establishing metrics of success, it is critical to consider how these metrics will be understood in the public arena.<sup>6</sup>

Success of RFA treatment can be determined objectively with volume reduction ratio (VRR) and thyroid

**TABLE 3** Potential outcome measures for ablation in benign thyroid nodules

	Nonfunctioning	Autonomously functioning
Quantitative measures		
Volume reduction ratio (VRR)	✓	✓
Serum TSH, free T4 <sup>a</sup>	✓ <sup>b</sup>	✓
Radioiodine uptake ( <sup>123</sup> I) scan		✓
Qualitative measures		
Symptom score (0–10)	✓	✓
Cosmetic score (1–4)	✓	✓
ThyPRO/ThyPRO-39	✓	✓
SF-36	✓	✓

<sup>a</sup>In the case of a benign nonfunctional nodule, measurement of T3 may also be necessary to identify/follow isolated T3 toxicosis.

<sup>b</sup>While the intent of RFA in benign nonfunctional disease is not to treat thyroid hormone dysfunction, preservation of pre-existing function should be assessed.

function studies, which are independent of patient participation.<sup>141</sup> However, because the decision to treat benign nodules is usually based on subjective complaints, it is meaningful to attempt to quantify the level of pre-intervention impairment.<sup>142</sup> Several validated instruments such as cosmetic questionnaires, quality of life (QOL) instruments, symptom scores, and even measures such as the number of treatments and complications may be utilized.<sup>2,143</sup> These measures of effect of therapy are discussed in greater detail in the “Pre-Procedural Evaluation” section and are included in Table 3.

Like with surgery, successful treatment of functional nodules involves achievement of a euthyroid state without antithyroid drugs or thyroid hormone replacement.<sup>144</sup> Persistent hyperthyroidism resulting from inadequate treatment is associated with long-term cardiovascular and skeletal morbidity and even mortality in older adults.<sup>145,146</sup> Reduction in antithyroid medication dosing should not be quantified as treatment success unless a euthyroid status is achieved and maintained. This may be especially challenging in larger nodules where durable remission is less likely<sup>3,51</sup>; in such cases, surgical resection or RAI may be the more appropriate definitive approach.

#### 7.1.2 | Malignant disease

Well-differentiated primary thyroid cancers generally have a favorable prognosis when managed surgically. Furthermore, in the hands of an experienced surgeon, complications are rare and outcomes are generally



excellent. The gold standard for surgical treatment is complete eradication of tumor. However, in recent decades, active surveillance has been increasingly embraced as a safe management strategy for low risk PTMCs.<sup>147</sup> In contrast to surgical resection, successful outcomes include lack of disease progression and ability to avoid surgery.

Preliminary studies evaluating the efficacy of thermal ablation techniques for treatment of unifocal PTMC demonstrate that, with careful patient selection, excellent volume reduction can be achieved, but complete sonographic disappearance is less consistent. Importantly, volume reduction and complete sonographic disappearance may not correspond to a complete elimination of carcinoma.<sup>148,149</sup> Indeed, among the limited histologic specimens of PTMC initially managed with RFA described to date, a majority have demonstrated persistent thyroid carcinoma, the clinical significance of which is unknown.<sup>149</sup> Long-term outcomes of RFA and other thermal techniques in the treatment of primary thyroid cancers must be better understood before RFA is routinely offered for management.

While surgical resection is likely to remain the gold standard for treatment of primary thyroid cancer, RFA may emerge as a potentially less invasive primary treatment for unifocal, low risk PTMCs, especially in patients who are poor surgical candidates or who decline surgery. Under such circumstances, the treatment objective would not be complete eradication of tumor, but prevention of disease progression and avoidance of surgery. As with active surveillance, careful patient selection is critical to the appropriate application and success of RFA in this setting.

For locoregionally persistent or recurrent thyroid cancer, the standard of care remains surgical resection, although RFA may be indicated for patients at high surgical risk, who have undergone multiple operations, or who decline surgery but clinically require intervention.<sup>2,150</sup>

Outcome metrics for RFA treatment of malignant nodules are summarized in Table 4.

Recommendation 12: Careful documentation of both objective and subjective metrics before treatment and

during the follow-up period is important to establish treatment effectiveness and to set realistic expectations.

Recommendation 13a: Following thermal ablation for benign nodules, primary objective measures of efficacy include ultrasonographic measurement of volume reduction and preservation or normalization of thyroid function.

Recommendation 13b: Patient-reported outcomes, including validated symptom, cosmetic, and quality of life instruments, may be used to determine efficacy.

Recommendation 13c: Repeat ablation of a benign nodule can be considered for remnant nodular tissue contributing to unresolved symptomatic or cosmetic concerns.

Recommendation 13d: Retreatment for persistent hyperthyroidism may be performed.

Recommendation 14: Following thermal ablation for recurrent malignancy, ultrasonographic determination of tumor volume, assessment of locoregional disease status, and serum Tg/TgAb are performed to evaluate treatment response.

Recommendation 15: In the setting of primary malignancy, sonographic volume reduction or complete resolution of the malignant lesion, along with long-term assessment of disease progression, are necessary to determine oncologic effect.

## 8 | EFFECTIVENESS OF ABLATION BY TECHNIQUE

### 8.1 | Radiofrequency ablation

For benign thyroid nodules, RFA appears the most effective US-guided ablation technique for treating solid, mixed, and spongiform nonfunctioning thyroid nodules. A meta-analysis of long-term outcomes in benign thyroid nodules reported a pooled volume reduction of 64.5% at 6 months and 76.9% at 12 months, followed by further volume reduction of 92.2% at 36 months.<sup>151</sup> This was accompanied by improvement in nodule-related symptoms and cosmesis.<sup>138</sup> Compared with surgery for benign thyroid nodules, RFA is associated with fewer complications, better health-related QOL, and improved preservation of thyroid function.<sup>152–154</sup>

Data addressing effectiveness of RFA therapy in treating hyperthyroidism associated with functional nodules are limited and, as of yet, lacks long-term follow-up. A recent meta-analysis reported TSH normalization in 71.2% after 12 months.<sup>99</sup> Patients with smaller nodules (<12 ml) and volume reduction exceeding 80% are more likely to be free of symptoms with resolution of hyperthyroidism.<sup>59</sup> In comparison with surgery, patients undergoing RFA for autonomously functioning nodules have lower rates of hypothyroidism and procedure-related

**TABLE 4** Potential outcome measures for ablation in recurrent malignancy and PTMC

Sonographic measures	Cytologic/histologic confirmation
Volume reduction ratio (VRR)	Fine needle aspiration biopsy (FNAB)
Complete disappearance (CD)	Core needle biopsy
Regional lymph node metastases	Surgical pathology

complications, although significantly fewer achieve thyroid function normalization.<sup>152,155</sup>

Numerous studies have demonstrated efficacy in the setting of recurrent/residual thyroid malignancy, with complete nodular disappearance ranging from 68% to 93%.<sup>44,47,70,73,86,156</sup> Recurrence-free survival is similar between RFA and re-operation, as are rates of post-treatment voice change. Long-term follow-up is limited, although a single institution study reported 91% of tumors remained radiographically absent after 5 or more years.<sup>157</sup> Furthermore, RFA may play a role in palliative symptomatic relief or slowing of local cancer progression, even where disappearance of disease is not achievable.

As discussed above in detail, RFA in primary thyroid cancer is a developing application. Data from a large cohort study of patients with unifocal PTMC reported complete sonographic disappearance in 88% of tumors, and average volume reduction of 98.8% after 42 months. Locoregional progression occurred in 3.6%.<sup>68</sup> Several additional studies demonstrate a comparable degree of efficacy in low-risk PTMC without evidence of metastatic disease.<sup>67,69,158,159</sup>

## 8.2 | Laser ablation

The use of LTA for the treatment of benign thyroid nodules was developed on experimental and clinical grounds in 2000,<sup>104</sup> and its efficacy has since been confirmed in a number of studies.<sup>160–164</sup> A large, multicenter study of 1534 nodules treated with LA reported volume reduction of 72%, with significant symptom and cosmetic improvement.<sup>165</sup> Conclusive evidence was provided by a multicenter prospective randomized trial of 200 patients that collectively demonstrated a 57% VRR at 36 months, with >50% reduction in 67% of cases, paralleled by local symptom improvement in the absence of thyroid function changes.<sup>163</sup>

LTA has also been studied in the treatment of autonomous functioning nodules. A prospective randomized study compared a single treatment of LTA to RAI in 30 patients with autonomous nodules and mild subclinical hyperthyroidism. While nodule size reduced by 44% in the LTA group, thermal ablation was significantly inferior to RAI in normalizing TSH.<sup>166</sup> Similar to RFA, greater clinical success in treating functional nodules is seen in patients with smaller nodules in whom substantial (>80%) volume reduction is achieved.<sup>167</sup>

The utility of LTA for the treatment of PTMC has not been extensively evaluated. A retrospective study has reported similar results to RFA, with 94% of lesions remaining radiographically absent and 5.6% of patients

demonstrating locoregional metastases over 4 years of follow-up.<sup>168</sup> A systematic review and meta-analysis of RFA, LTA, and MWA in PTMC reported results from treatment of 1284 lesions, confirming no significant differences between the three techniques in volume reduction or major complications.<sup>169</sup>

## 8.3 | Microwave ablation

MWA for thyroid nodules has been less robustly studied and has limited long term follow-up. Theoretical advantages of MWA over other thermal ablation techniques include reduction in treatment time due to larger ablation zone and less heat sink effect.<sup>170</sup> However, this may be coupled with greater risk of pain and adverse outcomes.<sup>171</sup> A retrospective study of 222 patients with 447 treated benign thyroid nodules showed a volume reduction >50% in 82.3% of nodules, and complete resolution of 30.7% of nodules at 6 months post ablation.<sup>22</sup> Additional high volume retrospective analyses report volume reduction between 67% and 74% at 6 months, and 80%–89% at 12 months following MWA.<sup>171,172</sup> A randomized prospective study demonstrated improved general and mental health scores at 12 and 24 months, as well as lower visual analogue pain scores, compared with surgery.<sup>173,174</sup> MWA in functional nodules has not been systematically addressed.

## 8.4 | High-intensity focused ultrasound

HIFU also lacks data from high quality prospective study. Two systematic reviews of HIFU for benign non-functional nodules reported pooled volume reductions of 45%–70% ranging from 3 to 24 months of follow-up.<sup>175</sup> A European multicenter retrospective study demonstrated a single session of HIFU to result in 30%–35% decrease in nodule volume.<sup>176</sup> As with other thermal ablation techniques, there is an inverse correlation between initial nodule size and final volume reduction.<sup>177,178</sup> Although limited by selection bias with much larger nodules in the surgical group, one retrospective study of HIFU compared to thyroid lobectomy for symptomatic benign nodules, showed volume reduction of 51.7% at 6 months post ablation, shorter hospital stay, lower cost, greater symptom improvement, and less impact on voice in the HIFU group.<sup>179</sup> There is limited data regarding the treatment of autonomously functioning nodules with HIFU, with single institution comparison of HIFU and RAI showing significantly improved scintigraphic response and resolution of hyperthyroidism in the RAI group.<sup>180</sup>

## 8.5 | Ethanol ablation

Aspiration followed by ethanol ablation is most appropriate in the ablation of cystic thyroid nodules.<sup>181</sup> Expected volume reduction ranges from 46% to upward of 90%.<sup>182–184</sup> Currently, due to the more predictable area of tissue destruction and ability to treat any solid component, thermal ablation procedures have superseded the use of ethanol ablation for solid thyroid nodules,<sup>3</sup> although ethanol can be combined with the thermal techniques in the treatment of mixed cystic and solid nodules. Ethanol can be particularly useful in low resources settings, as it is inexpensive and does not require specialized equipment.

Ethanol ablation has been successfully employed in select patients with recurrent/persistent well-differentiated thyroid malignancy to treat low volume metastatic disease in the neck.<sup>130,131,185</sup> Multiple sessions are typically required, with volume reduction that ranges from 30% to 100%.<sup>129</sup> Durability of lesion reduction has been proven in long-term follow-up exceeding 5 years.<sup>185,186</sup>

## 8.6 | Summary and implications of efficacy data

Overall, there is robust evidence based on prospective randomized trials and large, multi-institutional studies with long-term follow-up supporting the efficacy of RFA and LTA in the treatment of benign, nonfunctional thyroid disease. Their optimal roles in functional nodules and malignancy continue to evolve, and currently lack high-volume studies with long term follow-up. The available data for MWA and HIFU is generally of a lower level of evidence and primarily based on retrospective or single-center data. Table 5 summarizes the comparative efficacy of each technique in varied clinical settings, as well as an estimate of complexity as determined by necessary equipment, level of risk, and technical expertise.

The data presented does not represent a systematic literature review, but rather highlights what is currently achievable with ablation technology and serves to guide a physician's choice of modality. For all minimally invasive techniques, nodule composition, location, and intensity of internal vascularity influence long-term results.<sup>187</sup> Decision making should, therefore, also take into account the different learning curves, technical requirements, and relative equipment complexities associated with each technology. It is anticipated that a physician's early thermal ablation practice will be more conservative in an attempt to avoid complications and that measured results will, in time, match published data.

## 9 | POTENTIAL COMPLICATIONS

As with surgery, the proximity of the RLN to the thyroid and central compartment lymph nodes places it at risk for injury during ablation procedures. Because studies examining rates of RLN injury utilizing pre- and post-procedural laryngoscopy are lacking, accurate rates of RLN injury are difficult to ascertain. A systematic review and meta-analysis conducted by Chung et al.<sup>45</sup> identified a 1.44% overall rate of transient or permanent voice change following RFA based on subjective voice assessment. The rate of voice change was higher (7.95%) in the subset of 176 patients undergoing RFA for recurrent thyroid cancer, primarily in the central compartment. Injection of cold irrigant in the region of suspected thermal injury when voice change develops has been proposed as a management strategy for mitigating RLN injury.<sup>188</sup> It should be noted, however, that prior studies have reported hypothermic nerve damage with exposure to cold solutions.<sup>189,190</sup>

Special consideration is warranted in the patient for whom bilateral ablation in the thyroid or thyroid bed is being considered. A high level of scrutiny should be given to any voice change, and vocal fold examination is necessary prior to proceeding with the contralateral side.

**TABLE 5** Comparison of efficacy and complexity of ablative techniques

	Solid/ predominantly solid benign nodule	Cystic/ predominantly cystic benign nodule	Functional nodule	Primary malignancy (PTMC)	Recurrent malignancy
Radiofrequency	√√	√	√	√	√
EtOH	N/A	√√	√	√	√
Microwave	√	√	√	√	√
Laser	√	√	√	√	√
HIFU	√	N/A	√	N/A	N/A

Note: √, √√, or √√√ to designate efficacy of technology for each clinical condition (√√√ is most efficacious). N/A implies insufficient data to assess.

Edema within the treated nodule is expected transiently following RFA<sup>57</sup>; therefore, it may be safer to stage bilateral ablations to avoid consequences of delayed nerve palsy.

In addition to the RLN, other nerves are at risk of thermal injury during ablation of the thyroid and/or cervical lymph nodes. Although rare,<sup>45</sup> these include the vagus nerve in the carotid sheath, the sympathetic chain posterior to the carotid artery, the brachial plexus in the supraclavicular fossa, and the phrenic nerve on the deep neck musculature.

Thyroid nodule rupture after RFA has been reported as the second-most frequent complication occurring after voice change.<sup>45,191,192</sup> Delayed bleeding caused by microvessel leakage leading to nodule enlargement and thyroid capsule disruption has been proposed as the underlying mechanism.<sup>45,193</sup> Patients typically present with neck swelling and pain 2–4 weeks following the procedure. Conservative management is appropriate in the majority of cases.

Avoidance of hypothyroidism is a primary motivational factor in pursuing RFA over surgery. A multi-institutional study of 1459 patients with benign nodules identified treatment-related hypothyroidism in only one individual, associated with elevated antithyroid antibodies preprocedurally.<sup>192</sup> Hypothyroidism following ablation of an autonomously functional nodule is similarly rare.<sup>139</sup> Due to the focused nature of ablation, as well as the often unilateral approach, postprocedural hypoparathyroidism has not been reported.

Hematoma is typically the result of inadvertently traversing an anterior jugular or other significant perithyroidal vein, which should be identified by ultrasound prior to insertion of the needle electrode. Superficial burns may occur at the grounding pads, although are more common at the site of electrode contact and during ablation occurring too close to the skin. Tracheal necrosis and airway compromise can result from penetration of, or ablation in close proximity to, the trachea.<sup>194</sup>

Finally, performing thyroid RFA in either pregnant women or patients with implantable cardioverter-defibrillators (ICDs) warrants special deliberation. Monopolar electrodes, typically employed for thyroid RFA, allow for dispersion of electrical current. Consequently, experts have expressed concern for possible fetal injury occurring during RFA. The generated electrical waves can also potentially cause interference with ICD function, representing a lethal threat to patients who are dependent on an ICD to maintain a normal cardiac rhythm. No complications in either population have been reported in the literature; however, at present, data are insufficient. Given the theoretical risk, if one were to perform RFA in these patient populations, the use of bipolar electrodes, which minimize electrical spread, would be most appropriate.

Recommendation 16: Assiduous recording of complications resulting from thermal ablation is recommended in order to accurately inform practitioners and patients about the safety of these procedures.

## 10 | IMPLEMENTATION

RFA of the thyroid is a technique at the intersection of multiple disciplines, including endocrinology, radiology, and surgery/otolaryngology. The specialty of the physician, however, is less important than careful patient selection, familiarity with neck anatomy, and expertise in cervical US and US-guided procedures. Discussions must make clear that RFA is one of several management options for thyroid nodules, with the optimal approach for an individual patient being a measured consideration of multiple factors by patient and physician. Because of the varying training backgrounds among clinicians performing ablation, it is important to make sure that appropriate otolaryngologic backup is immediately available in the event of certain postprocedural complications including vocal fold paralysis, airway distress, or cervical hematoma. A collaborative multidisciplinary group is thus optimal for care of the patient undergoing US-guided ablation procedures.

First and foremost, clinicians planning to incorporate RFA into their practice must have a comprehensive understanding of diagnostic and interventional US of the neck. Ultrasonography is an operator-dependent process wherein success is determined by the education, motivation, and experience of the examiner. Initial exposure to ultrasonography often occurs during residency and postgraduate training. Depending on this background, the ability to perform diagnostic ultrasound may require more formal accreditation via courses associated with professional society meetings or continued education offerings.<sup>195</sup> Expertise is not based on training or certification alone, but is acquired through frequent, regular application of ultrasonography in the clinical setting.<sup>196</sup>

In addition, proficiency with US-guided FNAB of thyroid nodules is recommended. It is helpful to have specific experience with the transisthmic approach to biopsies prior to performing an RFA procedure. Attendance at one or more RFA workshops is advisable, wherein there is opportunity to practice the technique on phantoms and to observe an experienced practitioner perform the procedure on a patient. Identifying a suitable proctor before undertaking procedures independently is also advisable. Literature sources show a lower complication rate among practitioners with 50 or more cases.<sup>192</sup> Although there is no certification process to perform RFA, physicians seeking to responsibly incorporate this

technique into their practice should consider the training described as requisite. As there is not a standard minimum experience to establish competency in US-guided procedures, it may be necessary to define criteria for US-guided ablation privileges at an institutional level.

It is recognized that paths to procedural competence will vary according to specialty-specific training experiences and clinical practice. Overall, the ideal setting in which RFA is incorporated into practice is one that is equipped to care for the patient through the diagnostic, interventional, and surveillance process, providing an opportunity for follow-up and audit of patients treated. The performing physician may be a member of an integrated team capable of managing postprocedural clinical, radiographic, and biochemical expectations via regular communication. Multidisciplinary review of cases undergoing consideration for US-guided procedures may help to ensure all stakeholders in the disease management process are aligned throughout all phases of care.

Recommendation 17a: Prior to performing any US-guided thermal ablation procedure, advanced training in and facility with US of the thyroid and neck are essential.

Recommendation 17b: Proficiency with US-guided fine needle aspiration biopsies of thyroid nodules is recommended for performance of US-guided ablation procedures.

Recommendation 17c: The provider should receive specific instruction on the chosen ablation technique, with the opportunity to practice on a phantom model and observe cases.

Recommendation 17d: Optimal practice involves one's initial cases being supervised by a physician experienced in US-guided ablation procedures.

Recommendation 18: Physicians performing US-guided thyroid ablation who do not provide longitudinal patient care should communicate and facilitate long-term follow-up with a care team specializing in management of nodular thyroid disease.

## 11 | SUMMARY AND FUTURE DIRECTIONS

US-guided thermal ablation is increasingly employed as a safe, minimally invasive alternative to surgery or active surveillance for both benign and malignant pathologies of the thyroid. Standardization of practices and reporting has emerged as an important component of multidisciplinary application of these technologies. This document represents an international collaborative effort to synthesize best evidence and expert opinion and to serve as a resource for practical and safe application of thyroid ablation techniques. While RFA is the dominant focus of this statement, the clinical framework presented applies

to other ablation techniques, including LTA, MWA, HIFU, and ethanol ablation. Future efforts will elucidate patient- and nodule-specific factors in which one technique should be preferred over others. While all methods may be appropriate for some patients, not all clinicians should seek to offer each of these techniques.

Further investigation is required to address areas of evolving understanding, including:

- Optimal role of thermal ablation in primary malignancy and indeterminate nodules.
- Optimal role of thermal ablation vs. surgery in cytologically benign thyroid nodules.
- The role of thermal ablation in managing metastatic disease primarily.
- Criteria for determining treatment efficacy and outcomes.
- Prognostic factors for successful ablation and regrowth.
- Timing of additional treatment following an incomplete treatment or regrowth.
- Cost effectiveness for ablation procedures vs. surgical approaches.
- Patient-related outcome measures for ablation procedures versus surgical approaches.
- Comparative efficacy, safety, and ideal applications of varied thermal ablation techniques.
- Long-term efficacy in all clinical applications.
- Minimum expectations for training and experience prior to offering thermal ablation.
- Disseminating and securing global availability of ablation technologies.

As interest in ablation technologies grows among practitioners and patients, appropriate application of evidence-based principles and techniques should remain a priority.

### DATA AVAILABILITY STATEMENT

Data sharing is not applicable to this article as no new data were created or analyzed in this study.

### ORCID

Julia E. Noel  <https://orcid.org/0000-0001-9955-3315>

Brendan C. Stack Jr  <https://orcid.org/0000-0003-2896-1615>

Louise Davies  <https://orcid.org/0000-0001-5581-2813>

Emad Kandil  <https://orcid.org/0000-0001-5895-4403>

Dong Gyu Na  <https://orcid.org/0000-0001-6422-1652>

Jonathon O. Russell  <https://orcid.org/0000-0003-2903-9649>

Michael Singer  <https://orcid.org/0000-0002-8673-2637>

Jose Higino Steck  <https://orcid.org/0000-0001-9735-8647>

Kyung Tae  <https://orcid.org/0000-0002-0382-2072>

## REFERENCES

- Hahn SY, Shin JH, Na DG, et al. Ethanol ablation of the thyroid nodules: 2018 consensus statement by the Korean society of thyroid radiology. *Korean J Radiol.* 2019;20:609-620. doi:10.3348/kjr.2018.0696
- Kim J-H, Baek JH, Lim HK, et al. Thyroid radiofrequency ablation guideline: Korean Society of Thyroid Radiology. *Korean J Radiol.* 2017;19(4):632-655. doi:10.3348/kjr.2018.19.4.632
- Papini E, Monpeyssen H, Frasoldati A, Hegedüs L. European thyroid association clinical practice guideline for the use of image-guided ablation in benign thyroid nodules. *Eur Thyroid J.* 2020;9(4):172-185. doi:10.1159/000508484
- Papini E, Pacella CM, Solbiati LA, et al. Minimally-invasive treatments for benign thyroid nodules: a Delphi-based consensus statement from the Italian minimally-invasive treatments of the thyroid (MITT) group. *Int J Hyperthermia.* 2019;36(1):376-382. doi:10.1080/02656736.2019.1575482
- Dobnig H, Zechmann W, Hermann M, et al. Radiofrequency ablation of thyroid nodules: "good clinical practice recommendations" for Austria: an interdisciplinary statement from the following professional associations: Austrian Thyroid Association (ÖSDG), Austrian Society for Nuclear Medicine and Molecular Imaging (OGNMB), Austrian Society for Endocrinology and Metabolism (ÖGES), Surgical Endocrinology Working Group (ACE) of the Austrian Surgical Society (OEGCH). *Wien Med Wochenschr.* 2020;170:6-14. doi:10.1007/s10354-019-0682-2
- Mauri G, Pacella CM, Papini E, et al. Image-guided thyroid ablation: proposal for standardization of terminology and reporting criteria. *Thyroid.* 2019;29:611-618. doi:10.1089/thy.2018.0604
- Ahmed M, Solbiati L, Brace CL, et al. Image-guided tumor ablation: standardization of terminology and reporting criteria—a 10-year update. *J Vasc Interv Radiol.* 2014;27(1):241-260. doi:10.1016/j.jvir.2014.08.027
- Hegedüs L, Frasoldati A, Negro R, Papini E. European Thyroid Association survey on use of minimally invasive techniques for thyroid nodules. *Eur Thyroid J.* 2020;9:194-204. doi:10.1159/000506513
- Goldberg SN. Radiofrequency tumor ablation: principles and techniques. *Eur J Ultrasound.* 2001;13(2):129-147. doi:10.1016/S0929-8266(01)00126-4
- De Bernardi IC, Floridi C, Muollo A, et al. Vascular and interventional radiology radiofrequency ablation of benign thyroid nodules and recurrent thyroid cancers: literature review. *Radiol Med.* 2014;119(7):512-520. doi:10.1007/s11547-014-0411-2
- Shin JH, Baek JH, Ha EJ, Lee JH. Radiofrequency ablation of thyroid nodules: basic principles and clinical application. *Int J Endocrinol.* 2012;2012:919650. doi:10.1155/2012/919650
- Baek JH, Lee JH, Valcavi R, Pacella CM, Rhim H, Na DG. Thermal ablation for benign thyroid nodules: radiofrequency and laser. *Korean J Radiol.* 2011;12(5):525-540. doi:10.3348/kjr.2011.12.5.525
- Rhim H, Goldberg SN, Dodd GD, et al. Essential techniques for successful radio-frequency thermal ablation of malignant hepatic tumors. *Radiographics.* 2001;21:S17-S35. doi:10.1148/radiographics.21.suppl\_1.g01oc11s17
- Ha EJ, Baek JH, Lee JH. Moving-shot versus fixed electrode techniques for radiofrequency ablation: comparison in an ex vivo bovine liver tissue model. *Korean J Radiol.* 2014;15:836-843. doi:10.3348/kjr.2014.15.6.836
- Stafford RJ, Fuentes D, Elliott AA, Weinberg JS, Ahrar K. Laser-induced thermal therapy for tumor ablation. *Crit Rev Biomed Eng.* 2010;38:79-100. doi:10.1615/CritRevBiomedEng.v38.i1.70
- Schena E, Saccomandi P, Fong Y. Laser ablation for cancer: past, present and future. *J Funct Biomater.* 2017;8:19. doi:10.3390/jfb8020019
- Lubner MG, Brace CL, Hinshaw JL, Lee FT. Microwave tumor ablation: mechanism of action, clinical results, and devices. *J Vasc Interv Radiol.* 2010;21:S192-S203. doi:10.1016/j.jvir.2010.04.007
- Simon CJ, Dupuy DE, Mayo-Smith WW. Microwave ablation: principles and applications. *Radiographics.* 2005;25:S69-S83. doi:10.1148/rg.25Si055501
- Wright AS, Sampson LA, Warner TF, Mahvi DM, Lee FT. Radiofrequency versus microwave ablation in a hepatic porcine model. *Radiology.* 2005;236:132-139. doi:10.1148/radiol.2361031249
- Healey TT, March BT, Baird G, Dupuy DE. Microwave ablation for lung neoplasms: a retrospective analysis of long-term results. *J Vasc Interv Radiol.* 2017;28(2):206-211. doi:10.1016/j.jvir.2016.10.030
- Meloni MF, Chiang J, Laeseke PF, et al. Microwave ablation in primary and secondary liver tumours: technical and clinical approaches. *Int J Hyperthermia.* 2017;33:15-24. doi:10.1080/02656736.2016.1209694
- Yue W, Wang S, Wang B, et al. Ultrasound guided percutaneous microwave ablation of benign thyroid nodules: safety and imaging follow-up in 222 patients. *Eur J Radiol.* 2013;82(1):e11-e16. doi:10.1016/j.ejrad.2012.07.020
- Chen X, Wu W, Gong X, Zhou Q, Chen X. Ultrasound-guided percutaneous microwave ablation for solid benign thyroid nodules: comparison of MWA versus control group. *Int J Endocrinol.* 2017;2017:9724090. doi:10.1155/2017/9724090
- Feng B, Liang P, Cheng Z, et al. Ultrasound-guided percutaneous microwave ablation of benign thyroid nodules: experimental and clinical studies. *Eur J Endocrinol.* 2012;166:1031-1037. doi:10.1530/EJE-11-0966
- Wu W, Gong X, Zhou Q, Chen X, Shi B. US-guided percutaneous microwave ablation for the treatment of benign thyroid nodules. *Endocr J.* 2017;64:1079-1085. doi:10.1507/endocrj.EJ17-0152
- Liu YJ, Qian LX, Liu D, Zhao JF. Ultrasound-guided microwave ablation in the treatment of benign thyroid nodules in 435 patients. *Exp Biol Med.* 2017;242:1515-1523. doi:10.1177/1535370217727477
- Watson T. Ultrasound in contemporary physiotherapy practice. *Ultrasonics.* 2008;48:321-329. doi:10.1016/j.ultras.2008.02.004
- ter Haar G, Coussios C. High intensity focused ultrasound: physical principles and devices. *Int J Hyperthermia.* 2007;23:89-104. doi:10.1080/02656730601186138
- Kotewall N, Lang BHH. High-intensity focused ultrasound ablation as a treatment for benign thyroid diseases: the present and future. *Ultrasonography.* 2019;38:135-142. doi:10.14366/usg.18040
- ter Haar G. HIFU tissue ablation: concept and devices. *Adv Exp Med Biol.* 2016;880:3-20. doi:10.1007/978-3-319-22536-4\_1
- Ryu M, Shimamura Y, Kinoshita T, et al. Therapeutic results of resection, transcatheter arterial embolization and percutaneous transhepatic ethanol injection in 3225 patients with hepatocellular carcinoma: a retrospective multicenter study. *Jpn J Clin Oncol.* 1997;27:251-257. doi:10.1093/jcco/27.4.251

32. Dimaio CJ, Dewitt JM, Brugge WR. Ablation of pancreatic cystic lesions: the use of multiple endoscopic ultrasound-guided ethanol lavage sessions. *Pancreas*. 2011;40:664-668. doi:10.1097/MPA.0b013e3182128d06
33. Chen HH, Lin CJ, Wu CJ, et al. Chemical ablation of recurrent and persistent secondary hyperparathyroidism after subtotal parathyroidectomy. *Ann Surg*. 2011;253:786-790. doi:10.1097/SLA.0b013e318211ccc2
34. Bennedbæk FN, Karstrup S, Hegedüs L. Percutaneous ethanol injection therapy in the treatment of thyroid and parathyroid diseases. *Eur J Endocrinol*. 1997;136:240-250. doi:10.1530/eje.0.1360240
35. Karstrup S, Hegedüs L, Holm HH. Ultrasonically guided chemical parathyroidectomy in patients with primary hyperparathyroidism: a follow-up study. *Clin Endocrinol (Oxf)*. 1993;38:523-530. doi:10.1111/j.1365-2265.1993.tb00349.x
36. Shiina S, Tagawa K, Unuma T, et al. Percutaneous ethanol injection therapy for hepatocellular carcinoma. A histopathologic study. *Cancer*. 1991;68:1524-1530. doi:10.1002/1097-0142(19911001)68:7<1524::AID-CNCR2820680711>3.0.CO;2-O
37. Sharma A, Abraham D. Vascularity-targeted percutaneous ethanol injection of toxic thyroid adenomas: outcomes of a feasibility study performed in the USA. *Endocr Pract*. 2020;26:22-29. doi:10.4158/EP-2019-0329
38. Morhard R, Nief C, Barrero Castedo C, et al. Development of enhanced ethanol ablation as an alternative to surgery in treatment of superficial solid tumors. *Sci Rep*. 2017;7:8750. doi:10.1038/s41598-017-09371-2
39. Ahmed M, Brace CL, Lee FT, Goldberg SN. Principles of and advances in percutaneous ablation. *Radiology*. 2011;258:351-369. doi:10.1148/radiol.10081634
40. Tsai WL, Cheng JS, Lai KH, et al. Clinical trial: percutaneous acetic acid injection vs. percutaneous ethanol injection for small hepatocellular carcinoma—a long-term follow-up study. *Aliment Pharmacol Ther*. 2008;28:304-311. doi:10.1111/j.1365-2036.2008.03702.x
41. Yoon HM, Baek JH, Lee JH, et al. Combination therapy consisting of ethanol and radiofrequency ablation for predominantly cystic thyroid nodules. *Am J Neuroradiol*. 2014;35:582-586. doi:10.3174/ajnr.A3701
42. Shankar S, VanSonnenberg E, Morrison PR, Tuncali K, Silverman SG. Combined radiofrequency and alcohol injection for percutaneous hepatic tumor ablation. *Am J Roentgenol*. 2004;183:1425-1429. doi:10.2214/ajr.183.5.1831425
43. Shiina S, Sato K, Tateishi R, et al. Percutaneous ablation for hepatocellular carcinoma: comparison of various ablation techniques and surgery. *Can J Gastroenterol Hepatol*. 2018;2018:4756147. doi:10.1155/2018/4756147
44. Suh CH, Baek JH, Choi YJ, Lee JH. Efficacy and safety of radiofrequency and ethanol ablation for treating locally recurrent thyroid cancer: a systematic review and meta-analysis. *Thyroid*. 2016;26(3):420-428. doi:10.1089/thy.2015.0545
45. Chung SR, Suh CH, Baek JH, Park HS, Choi YJ, Lee JH. Safety of radiofrequency ablation of benign thyroid nodules and recurrent thyroid cancers: a systematic review and meta-analysis. *Int J Hyperthermia*. 2017;33:1-35. doi:10.1080/02656736.2017.1337936
46. Dobnig H, Amrein K. Monopolar radiofrequency ablation of thyroid nodules: a prospective Austrian single-center study. *Thyroid*. 2018;28:472-480. doi:10.1089/thy.2017.0547
47. Zhao Q, Tian G, Kong D, Jiang T. Meta-analysis of radiofrequency ablation for treating the local recurrence of thyroid cancers. *J Endocrinol Invest*. 2016;39:909-916. doi:10.1007/s40618-016-0450-8
48. Jeong SY, Baek JH, Choi YJ, Lee JH. Ethanol and thermal ablation for malignant thyroid tumours. *Int J Hyperthermia*. 2017;33:938-945. doi:10.1080/02656736.2017.1361048
49. Dalkey N, Helmer O. An experimental application of the DELPHI method to the use of experts. *Manage Sci*. 1963;9:351-515. doi:10.1287/mnsc.9.3.458
50. Dalkey N. The Delphi method: an experimental study of group opinion. *Studies in the Quality of Life: Delphi and Decision-Making*; Lexington Books; 1972.
51. Garberoglio R, Aliberti C, Appetecchia M, et al. Radiofrequency ablation for thyroid nodules: Which indications? The first Italian opinion statement. *J Ultrasound*. 2015;18(4):423-430. doi:10.1007/s40477-015-0169-y
52. Jenkinson C, Coulter A, Wright L. Short form 36 (SF 36) health survey questionnaire: normative data for adults of working age. *Br Med J*. 1993;306(6890):1437-1440. doi:10.1136/bmj.306.6890.1437
53. Watt T, Bjorner JB, Groenvold M, et al. Development of a short version of the thyroid-related patient-reported outcome ThyPRO. *Thyroid*. 2015;25:1069-1079. doi:10.1089/thy.2015.0209
54. Bernardi S, Stacul F, Michelli A, et al. 12-month efficacy of a single radiofrequency ablation on autonomously functioning thyroid nodules. *Endocrine*. 2017;11:317. doi:10.1007/s12020-016-1174-4
55. Cesareo R, Palermo A, Benvenuto D, et al. Efficacy of radiofrequency ablation in autonomous functioning thyroid nodules. A systematic review and meta-analysis. *Rev Endocr Metab Disord*. 2019;20:37-44. doi:10.1007/s11154-019-09487-y
56. Cervelli R, Mazzeo S, Boni G, et al. Comparison between radioiodine therapy and single-session radiofrequency ablation of autonomously functioning thyroid nodules: a retrospective study. *Clin Endocrinol (Oxf)*. 2019;90:608-616. doi:10.1111/cen.13938
57. Deandrea M, Limone P, Basso E, et al. US-guided percutaneous radiofrequency thermal ablation for the treatment of solid benign hyperfunctioning or compressive thyroid nodules. *Ultrasound Med Biol*. 2008;34:784-791. doi:10.1016/j.ultrasmedbio.2007.10.018
58. Bonnema SJ, Hegedüs L. Radioiodine therapy in benign thyroid diseases: effects, side effects, and factors affecting therapeutic outcome. *Endocr Rev*. 2012;33:920-980. doi:10.1210/er.2012-1030
59. Cesareo R, Palermo A, Pasqualini V, et al. Radiofrequency ablation on autonomously functioning thyroid nodules: a critical appraisal and review of the literature. *Front Endocrinol (Lausanne)*. 2020;11:317. doi:10.3389/fendo.2020.00317
60. Lang BHH, Woo YC, Wong IYH, Chiu KWH. Single-session high-intensity focused ultrasound treatment for persistent or relapsed graves disease: preliminary experience in a prospective study. *Radiology*. 2017;285:1011-1022. doi:10.1148/radiol.2017162776
61. National Institute for Health and Care Excellence. *Ultrasound-Guided Percutaneous Radiofrequency Ablation for Benign Thyroid Nodules. Interventional Procedure Guidance [IPT562]*. National Institute for Health and Care Excellence; 2016 <https://www.nice.org.uk/>
62. Ruzzenente A, de Manzon G, Molfetta M, et al. Rapid progression of hepatocellular carcinoma after radiofrequency ablation. *World J Gastroenterol*. 2004;10:1137-1140. doi:10.3748/wjg.v10.i8.1137

63. Kong J, Kong J, Pan B, et al. Insufficient radiofrequency ablation promotes angiogenesis of residual hepatocellular carcinoma via HIF-1 $\alpha$ /VEGFA. *PLoS One*. 2012;7:e37266. doi:10.1371/journal.pone.0037266
64. Kong J, Kong L, Kong J, et al. After insufficient radiofrequency ablation, tumor-associated endothelial cells exhibit enhanced angiogenesis and promote invasiveness of residual hepatocellular carcinoma. *J Transl Med*. 2012;10:230. doi:10.1186/1479-5876-10-230
65. Ke S, Ding X, Kong J, et al. Low temperature of radiofrequency ablation at the target sites can facilitate rapid progression of residual hepatic VX2 carcinoma. *J Transl Med*. 2010;8:73. doi:10.1186/1479-5876-8-73
66. Dobrinja C, Bernardi S, Fabris B, et al. Surgical and pathological changes after radiofrequency ablation of thyroid nodules. *Int J Endocrinol*. 2015;2015:576576. doi:10.1155/2015/576576
67. Lim HK, Cho SJ, Baek JH, et al. US-guided radiofrequency ablation for low-risk papillary thyroid microcarcinoma: efficacy and safety in a large population. *Korean J Radiol*. 2019;20:1653-1661. doi:10.3348/kjr.2019.0192
68. Yan L, Lan Y, Xiao J, Lin L, Jiang B, Luo Y. Long-term outcomes of radiofrequency ablation for unifocal low-risk papillary thyroid microcarcinoma: a large cohort study of 414 patients. *Eur Radiol*. 2020;31:685-694. doi:10.1007/s00330-020-07128-6
69. Zhang M, Luo Y, Zhang Y, Tang J. Efficacy and safety of ultrasound-guided radiofrequency ablation for treating low-risk papillary thyroid microcarcinoma: a prospective study. *Thyroid*. 2016;26:1581-1587. doi:10.1089/thy.2015.0471
70. Lee SJ, Jung SL, Kim BS, et al. Radiofrequency ablation to treat loco-regional recurrence of well-differentiated thyroid carcinoma. *Korean J Radiol*. 2014;15:817-826. doi:10.3348/kjr.2014.15.6.817
71. Mauri G, Hegedus L, Bandula S, et al. European Thyroid Association and Cardiovascular and Interventional Radiological Society of Europe 2021 clinical practice guideline for the use of minimally invasive treatments in malignant thyroid lesions. *Eur Thyroid J*. 2021;10:185-197. doi:10.1159/000516469
72. Hegedüs L, Miyauchi A, Tuttle RM. Nonsurgical thermal ablation of thyroid nodules: not if, but why, when, and how? *Thyroid*. 2020;30:1691-1694. doi:10.1089/thy.2020.0659
73. Kim JH, Yoo WS, Park YJ, et al. Efficacy and safety of radiofrequency ablation for treatment of locally recurrent thyroid cancers smaller than 2 cm. *Radiology*. 2015;276:909-918. doi:10.1148/radiol.15140079
74. Gharib H, Hegedüs L, Pacella CM, Baek JH, Papini E. Nonsurgical, image-guided, minimally invasive therapy for thyroid nodules. *J Clin Endocrinol Metab*. 2013;98:3949-3957. doi:10.1210/jc.2013-1806
75. Park HS, Baek JH, Choi YJ, Lee JH. Innovative techniques for image-guided ablation of benign thyroid nodules: combined ethanol and radiofrequency ablation. *Korean J Radiol*. 2017;18:461-469. doi:10.3348/kjr.2017.18.3.461
76. Noel JE, Orloff LA. Neck ultrasound: anatomical landmarks for safe performance of neck RFA. *Curr Otorhinolaryngol Rep*. 2021;9:60-64. doi:10.1007/s40136-020-00316-4
77. De Bodt MS, Wuyts FL, Van De Heyning PH, Croux C. Test-retest study of the GRBAS scale: influence of experience and professional background on perceptual rating of voice quality. *J Voice*. 1997;11:74-80. doi:10.1016/S0892-1997(97)80026-4
78. Eadie TL, Kapsner M, Rosenzweig J, Waugh P, Hillel A, Merati A. The role of experience on judgments of dysphonia. *J Voice*. 2010;24:564-573. doi:10.1016/j.jvoice.2008.12.005
79. Chandrasekhar SS, Randolph GW, Seidman MD, et al. Clinical practice guideline: improving voice outcomes after thyroid surgery. *Otolaryngol - Head Neck Surg (United States)*. 2013;148:S1-S37. doi:10.1177/0194599813487301
80. Arffa RE, Krishna P, Gartner-Schmidt J, Rosen CA. Normative values for the voice handicap index-10. *J Voice*. 2012;26:462-465. doi:10.1016/j.jvoice.2011.04.006
81. Hogikyan ND, Sethuraman G. Validation of an instrument to measure voice-related quality of life (V-RQOL). *J Voice*. 1999;13:557-569. doi:10.1016/S0892-1997(99)80010-1
82. Sinclair CF, Bumpous JM, Haugen BR, et al. Laryngeal examination in thyroid and parathyroid surgery: an American Head and Neck Society consensus statement. *Head Neck*. 2016;38(6):811-819. doi:10.1002/hed.24409
83. Dossa F, Dubé C, Tinmouth J, et al. Practice recommendations for the use of sedation in routine hospital-based colonoscopy. *BMJ Open Gastroenterol*. 2020;7:e000348. doi:10.1136/bmjgast-2019-000348
84. Shaw JR, Kaplovitch E, Douketis J. Periprocedural management of oral anticoagulation. *Med Clin North Am*. 2020;104:709-726. doi:10.1016/j.mcna.2020.02.005
85. Hinkelbein J, Lamperti M, Akeson J, et al. European Society of Anaesthesiology and European Board of Anaesthesiology guidelines for procedural sedation and analgesia in adults. *Eur J Anaesthesiol*. 2018;35:6-24. doi:10.1097/EJA.0000000000000683
86. Na DG, Lee JH, Jung SL, et al. Radiofrequency ablation of benign thyroid nodules and recurrent thyroid cancers: consensus statement and recommendations. *Korean J Radiol*. 2012;13:117-125. doi:10.3348/kjr.2012.13.2.117
87. Kim J, Baek JH, Lim HK, Na DG. Summary of the 2017 thyroid radiofrequency ablation guideline and comparison with the 2012 guideline. *Ultrasonography*. 2019;38:125-134. doi:10.14366/usg.18044
88. Park HS, Baek JH, Park AW, Chung SR, Choi YJ, Lee JH. Thyroid radiofrequency ablation: updates on innovative devices and techniques. *Korean J Radiol*. 2017;18:615-623. doi:10.3348/kjr.2017.18.4.615
89. Gitman M, Fettiplace MR, Weinberg GL, Neal JM, Barrington MJ. Local anesthetic systemic toxicity: a narrative literature review and clinical update on prevention, diagnosis, and management. *Plast Reconstr Surg*. 2019;144:783-795. doi:10.1097/PRS.0000000000005989
90. Neal JM, Barrington MJ, Fettiplace MR, et al. The Third American Society of Regional Anesthesia and Pain Medicine practice advisory on local anesthetic systemic toxicity: executive summary 2017. *Reg Anesth Pain Med*. 2018;43:113-123. doi:10.1097/AAP.0000000000000720
91. Laeseke PF, Sampson LA, Brace CL, Winter TC, Fine JP, Lee FT. Unintended thermal injuries from radiofrequency ablation: protection with 5% dextrose in water. *Am J Roentgenol*. 2006;186:S249-S254. doi:10.2214/AJR.04.1240
92. Laeseke PF, Sampson LA, Winter TC, Lee FT. Use of dextrose 5% in water instead of saline to protect against inadvertent radiofrequency injuries. *Am J Roentgenol*. 2005;184:1026-1027. doi:10.2214/ajr.184.3.01841026
93. Bernardi S, Lanzillotti V, Papa G, et al. Full-thickness skin burn caused by radiofrequency ablation of a benign



- thyroid nodule. *Thyroid*. 2016;26:183-184. doi:10.1089/thy.2015.0453
94. Huh JY, Baek JH, Choi H, Kim JK, Lee JH. Symptomatic benign thyroid nodules: efficacy of additional radiofrequency ablation treatment session—prospective randomized study. *Radiology*. 2012;263:909-916. doi:10.1148/radiol.12111300
  95. Ahn HS, Kim SJ, Park SH, Seo M. Radiofrequency ablation of benign thyroid nodules: evaluation of the treatment efficacy using ultrasonography. *Ultrasonography*. 2016;35:244-252. doi:10.14366/usg.15083
  96. Ha EJ, Baek JH, Lee JH. Ultrasonography-based thyroidal and perithyroidal anatomy and its clinical significance. *Korean J Radiol*. 2015;16:749-766. doi:10.3348/kjr.2015.16.4.749
  97. Offi C, Garberoglio S, Antonelli G, et al. The ablation of thyroid nodule's afferent arteries before radiofrequency ablation: preliminary data. *Front Endocrinol (Lausanne)*. 2021;11:565000. doi:10.3389/fendo.2020.565000
  98. Zhao CK, Xu HX, Lu F, et al. Factors associated with initial incomplete ablation for benign thyroid nodules after radiofrequency ablation: first results of CEUS evaluation. *Clin Hemorheol Microcirc*. 2017;65:393-405. doi:10.3233/CH-16208
  99. Kim HJ, Cho SJ, Baek JH, Suh CH. Efficacy and safety of thermal ablation for autonomously functioning thyroid nodules: a systematic review and meta-analysis. *Eur Radiol*. 2020;31:605-615. doi:10.1007/s00330-020-07166-0
  100. Lim HK, Baek JH, Lee JH, et al. Efficacy and safety of radiofrequency ablation for treating locoregional recurrence from papillary thyroid cancer. *Eur Radiol*. 2015;25:163-170. doi:10.1007/s00330-014-3405-5
  101. Xiaoyin T, Ping L, Dan C, et al. Risk assessment and hydrodissection technique for radiofrequency ablation of thyroid benign nodules. *J Cancer*. 2018;9:3058-3066. doi:10.7150/jca.26060
  102. Lee J, Shin JH, Hahn SY, Park KW, Choi JS. Feasibility of adjustable electrodes for radiofrequency ablation of benign thyroid nodules. *Korean J Radiol*. 2020;21:377-383. doi:10.3348/kjr.2019.0724
  103. Turtulici G, Orlandi D, Corazza A, et al. Percutaneous radiofrequency ablation of benign thyroid nodules assisted by a virtual needle tracking system. *Ultrasound Med Biol*. 2014;40:1447-1452. doi:10.1016/j.ultrasmedbio.2014.02.017
  104. Pacella CM, Bizzarri G, Guglielmi R, et al. Thyroid tissue: US-guided percutaneous interstitial laser ablation—a feasibility study. *Radiology*. 2000;217:673-677. doi:10.1148/radiology.217.3.r00dc09673
  105. Døssing H, Bennedbæk FN, Hegedüs L. Effect of ultrasound-guided interstitial laser photocoagulation on benign solitary solid cold thyroid nodules—a randomised study. *Eur J Endocrinol*. 2005;152:341-345. doi:10.1530/eje.1.01865
  106. Døssing H, Bennedbæk FN, Hegedüs L. Beneficial effect of combined aspiration and interstitial laser therapy in patients with benign cystic thyroid nodules: a pilot study. *Br J Radiol*. 2006;79:943-947. doi:10.1259/bjr/40698061
  107. Pacella CM, Bizzari G, Spiezia S, et al. Thyroid tissue: US-guided percutaneous laser thermal ablation. *Radiology*. 2004;232:272-280. doi:10.1148/radiol.2321021368
  108. Yue WW, Wang SR, Lu F, et al. Radiofrequency ablation vs. microwave ablation for patients with benign thyroid nodules: a propensity score matching study. *Endocrine*. 2017;55:485-495. doi:10.1007/s12020-016-1173-5
  109. Cheng Z, Che Y, Yu S, et al. US-guided percutaneous radiofrequency versus microwave ablation for benign thyroid nodules: a prospective multicenter study. *Sci Rep*. 2017;7:9554. doi:10.1038/s41598-017-09930-7
  110. Heck K, Happel C, Grünwald F, Korkusuz H. Percutaneous microwave ablation of thyroid nodules: effects on thyroid function and antibodies. *Int J Hyperthermia*. 2015;31:560-567. doi:10.3109/02656736.2015.1032371
  111. Korkusuz H, Happel C, Koch DA, Gruenwald F. Combination of ultrasound-guided percutaneous microwave ablation and radioiodine therapy in benign thyroid disease: a 3-month follow-up study. *RoFo*. 2016;188:60-68. doi:10.1055/s-0041-106538
  112. Wang B, Han ZY, Yu J, et al. Factors related to recurrence of the benign non-functioning thyroid nodules after percutaneous microwave ablation. *Int J Hyperthermia*. 2017;33:459-464. doi:10.1080/02656736.2016.1274058
  113. Palyga I, Palyga R, Mlynarczyk J, Kopczynski J, Gózdź S, Kowalska A. The current state and future perspectives of high intensity focused ultrasound (HIFU) ablation for benign thyroid nodules. *Gland Surg*. 2020;9:S95-S104. doi:10.21037/g.2019.10.16
  114. Lang BH, Wu ALH. The efficacy and safety of high-intensity focused ultrasound ablation of benign thyroid nodules. *Ultrasonography*. 2018;61:1636-1643. doi:10.14366/usg.17057
  115. Korkusuz H, Fehre N, Sennert M, Happel C, Grünwald F. Volume reduction of benign thyroid nodules 3 months after a single treatment with high-intensity focused ultrasound (HIFU). *J Ther Ultrasound*. 2015;3:4. doi:10.1186/s40349-015-0024-9
  116. Kovatcheva RD, Vlahov JD, Stoinov JI, Zaletel K. Benign solid thyroid nodules: US-guided high-intensity focused ultrasound ablation—initial clinical outcomes. *Radiology*. 2015;276:597-605. doi:10.1148/radiol.15141492
  117. Kim YJ, Baek JH, Ha EJ, et al. Cystic versus predominantly cystic thyroid nodules: efficacy of ethanol ablation and analysis of related factors. *Eur Radiol*. 2012;22:1573-1578. doi:10.1007/s00330-012-2406-5
  118. Sung JY, Kim YS, Choi H, Lee JH, Baek JH. Optimum first-line treatment technique for benign cystic thyroid nodules: ethanol ablation or radiofrequency ablation? *Am J Roentgenol*. 2011;196:W210-W214. doi:10.2214/AJR.10.5172
  119. Ko ES, Sung JY, Shin JH. Intralesional saline injection for effective ultrasound-guided aspiration of benign viscous cystic thyroid nodules. *Ultrasonography*. 2014;33:122-127. doi:10.14366/usg.13027
  120. Yasuda K, Ozaki O, Sugino K, et al. Treatment of cystic lesions of the thyroid by ethanol instillation. *World J Surg*. 1992;16:958-961. doi:10.1007/BF02067001
  121. Baek JH, Kim YS, Sung JY, Choi H, Lee JH. Locoregional control of metastatic well-differentiated thyroid cancer by ultrasound-guided radiofrequency ablation. *Am J Roentgenol*. 2011;197:W331-W336. doi:10.2214/AJR.10.5345
  122. Verde G, Papini E, Pacella CM, et al. Ultrasound guided percutaneous ethanol injection in the treatment of cystic thyroid nodules. *Clin Endocrinol (Oxf)*. 1994;41:719-724. doi:10.1111/j.1365-2265.1994.tb02785.x
  123. Monzani F, Lippi F, Goletti O, et al. Percutaneous aspiration and ethanol sclerotherapy for thyroid cysts. *J Clin Endocrinol Metab*. 1994;78(3):800-802. doi:10.1210/jc.78.3.800

124. Zingrillo M, Torlontano M, Ghiggi MR, et al. Percutaneous ethanol injection of large thyroid cystic nodules. *Thyroid*. 1996;6:403-408. doi:10.1089/thy.1996.6.403
125. Kim DW, Rho MH, Kim HJ, Kwon JS, Sung YS, Lee SW. Percutaneous ethanol injection for benign cystic thyroid nodules: is aspiration of ethanol-mixed fluid advantageous? *Am J Neuroradiol*. 2005;26:2122-2127.
126. Park HS, Yim Y, Baek JH, Choi YJ, Shong YK, Lee JH. Ethanol ablation as a treatment strategy for benign cystic thyroid nodules: a comparison of the ethanol retention and aspiration techniques. *Ultrasonography*. 2019;38:166-171. doi:10.14366/usg.18033
127. Sung JY, Baek JH, Kim KS, et al. Single-session treatment of benign cystic thyroid nodules with ethanol versus radiofrequency ablation: a prospective randomized study. *Radiology*. 2013;269:293-300. doi:10.1148/radiol.13122134
128. Guenette JP, Monchik JM, Dupuy DE. Image-guided ablation of postsurgical locoregional recurrence of biopsy-proven well-differentiated thyroid carcinoma. *J Vasc Interv Radiol*. 2013;24:672-679. doi:10.1016/j.jvir.2013.02.001
129. Kim BM, Kim MJ, Kim EK, Il PS, Park CS, Chung WY. Controlling recurrent papillary thyroid carcinoma in the neck by ultrasonography-guided percutaneous ethanol injection. *Eur Radiol*. 2008;18:835-842. doi:10.1007/s00330-007-0809-5
130. Heilo A, Sigstad E, Fagerlid KH, et al. Efficacy of ultrasound-guided percutaneous ethanol injection treatment in patients with a limited number of metastatic cervical lymph nodes from papillary thyroid carcinoma. *J Clin Endocrinol Metab*. 2011;96:2750-2755. doi:10.1210/jc.2010-2952
131. Lewis BD, Hay ID, Charboneau JW, McIver B, Reading CC, Goellner JR. Percutaneous ethanol injection for treatment of cervical lymph node metastases in patients with papillary thyroid carcinoma. *Am J Roentgenol*. 2002;178:699-704. doi:10.2214/ajr.178.3.1780699
132. Chi YL, Yun JS, Lee J, Nam KH, Woong YC, Cheong SP. Percutaneous ethanol injection therapy for locally recurrent papillary thyroid carcinoma. *Thyroid*. 2007;17:347-350. doi:10.1089/thy.2006.0251
133. Carneiro-Pla D, Miller BS, Wilhelm SM, et al. Feasibility of surgeon-performed transcatheter vocal cord ultrasonography in identifying vocal cord mobility: a multi-institutional experience. *Surgery*. 2014;156(6):1597-1604. doi:10.1016/j.surg.2014.08.071
134. Kandil E, Deniwar A, Noureldine SI, et al. Assessment of vocal fold function using transcatheter laryngeal ultrasonography and flexible laryngoscopy. *JAMA Otolaryngol Head Neck Surg*. 2016;142:74-78. doi:10.1001/jamaoto.2015.2795
135. Spiezia S, Garberoglio R, Milone F, et al. Thyroid nodules and related symptoms are stably controlled two years after radiofrequency thermal ablation. *Thyroid*. 2009;19:219-225. doi:10.1089/thy.2008.0202
136. Sim JS, Baek JH, Lee J, Cho W, Il JS. Radiofrequency ablation of benign thyroid nodules: depicting early sign of regrowth by calculating vital volume. *Int J Hyperthermia*. 2017;33:905-910. doi:10.1080/02656736.2017.1309083
137. Bernardi S, Giudici F, Cesareo R, et al. Five-year results of radiofrequency and laser ablation of benign thyroid nodules: a multicenter study from the Italian minimally invasive treatments of the thyroid group. *Thyroid*. 2020;30:1759-1770. doi:10.1089/thy.2020.0202
138. Jeong WK, Baek JH, Rhim H, et al. Radiofrequency ablation of benign thyroid nodules: safety and imaging follow-up in 236 patients. *Eur Radiol*. 2008;18(6):1244-1250. doi:10.1007/s00330-008-0880-6
139. Baek JH, Moon WJ, Kim YS, Lee JH, Lee D. Radiofrequency ablation for the treatment of autonomously functioning thyroid nodules. *World J Surg*. 2009;33:1971-1977. doi:10.1007/s00268-009-0130-3
140. Ha SM, Shin JY, Baek JH, et al. Does radiofrequency ablation induce neoplastic changes in benign thyroid nodules: a preliminary study. *Endocrinol Metab*. 2019;34:169-178. doi:10.3803/EnM.2019.34.2.169
141. Lee GM, You JY, Kim HY, et al. Successful radiofrequency ablation strategies for benign thyroid nodules. *Endocrine*. 2019;64:316-321. doi:10.1007/s12020-018-1829-4
142. Özden S, Er S, Tez M. Letter to "Successful radiofrequency ablation strategies for benign thyroid nodules". *Endocrine*. 2019;64:316-321. doi:10.1007/s12020-019-01879-z
143. Valcavi R, Tsamatropoulos P. Health-related quality of life after percutaneous radiofrequency ablation of cold, solid, benign thyroid nodules: a 2-year follow-up study in 40 patients. *Endocr Pract*. 2015;21:887-896. doi:10.4158/EP15676.OR
144. Pace-Asciak P, Russell JO, Shaeer M, Tufano RP. Novel approaches for treating autonomously functioning thyroid nodules. *Front Endocrinol (Lausanne)*. 2020;11:565371. doi:10.3389/fendo.2020.565371
145. Lillevang-Johansen M, Abrahamsen B, Jørgensen HL, Brix TH, Hegedüs L. Excess mortality in treated and untreated hyperthyroidism is related to cumulative periods of low serum TSH. *J Clin Endocrinol Metab*. 2017;102:2301-2309. doi:10.1210/jc.2017-00166
146. Lillevang-Johansen M, Abrahamsen B, Jørgensen HL, Brix TH, Hegedüs L. Duration of over- and under-treatment of hypothyroidism is associated with increased cardiovascular risk. *Eur J Endocrinol*. 2019;180:407-416. doi:10.1530/EJE-19-0006
147. Oda H, Miyauchi A, Ito Y, et al. Incidences of unfavorable events in the management of low-risk papillary microcarcinoma of the thyroid by active surveillance versus immediate surgery. *Thyroid*. 2016;26:150-155. doi:10.1089/thy.2015.0313
148. Valcavi R, Piana S, Bortolan GS, Lai R, Barbieri V, Negro R. Ultrasound-guided percutaneous laser ablation of papillary thyroid microcarcinoma: a feasibility study on three cases with pathological and immunohistochemical evaluation. *Thyroid*. 2013;23:1578-1582. doi:10.1089/thy.2013.0279
149. Ma B, Wei W, Xu W, et al. Surgical confirmation of incomplete treatment for primary papillary thyroid carcinoma by percutaneous thermal ablation: a retrospective case review and literature review. *Thyroid*. 2018;28:1134-1142. doi:10.1089/thy.2017.0558
150. Xu D, Ge M, Yang A, et al. Expert consensus workshop report: guidelines for thermal ablation of thyroid tumors (2019 edition). *J Cancer Res Ther*. 2020;16:960-966. doi:10.4103/jcrt.JCRT\_558\_19
151. Cho SJ, Baek JH, Chung SR, Choi YJ, Lee JH. Long-term results of thermal ablation of benign thyroid nodules: a systematic review and meta-analysis. *Endocrinol Metab*. 2020;35:339-350. doi:10.3803/EnM.2020.35.2.339
152. Che Y, Jin S, Shi C, et al. Treatment of benign thyroid nodules: comparison of surgery with radiofrequency ablation. *Am J Neuroradiol*. 2015;36(7):1321-1325. doi:10.3174/ajnr.A4276

153. Bernardi S, Dobrinja C, Fabris B, et al. Radiofrequency ablation compared to surgery for the treatment of benign thyroid nodules. *Int J Endocrinol*. 2014;2014:934595. doi:10.1155/2014/934595
154. Yue WW, Li XL, Xu HX, et al. Quality of life and cost-effectiveness of radiofrequency ablation versus open surgery for benign thyroid nodules: a retrospective cohort study. *Sci Rep*. 2016;6:37838. doi:10.1038/srep37838
155. Bernardi S, Dobrinja C, Carere A, et al. Patient satisfaction after thyroid RFA versus surgery for benign thyroid nodules: a telephone survey. *Int J Hyperthermia*. 2018;35:150-158. doi:10.1080/02656736.2018.1487590
156. Shin JE, Baek JH, Lee JH. Radiofrequency and ethanol ablation for the treatment of recurrent thyroid cancers: current status and challenges. *Curr Opin Oncol*. 2013;25(1):14-19. doi:10.1097/CCO.0b013e32835a583d
157. Chung SR, Baek JH, Choi YJ, Lee JH. Longer-term outcomes of radiofrequency ablation for locally recurrent papillary thyroid cancer. *Eur Radiol*. 2019;29:4897-4903. doi:10.1007/s00330-019-06063-5
158. Wu R, Luo Y, Tang J, et al. Ultrasound-guided radiofrequency ablation for papillary thyroid microcarcinoma: a retrospective analysis of 198 patients. *Int J Hyperthermia*. 2020;37:168-174. doi:10.1080/02656736.2019.1708480
159. Cho SJ, Baek SM, Lim HK, Lee KD, Son JM, Baek JH. Long-term follow-up results of ultrasound-guided radiofrequency ablation for low-risk papillary thyroid microcarcinoma: more than 5-year follow-up for 84 tumors. *Thyroid*. 2020;30:1745-1751. doi:10.1089/thy.2020.0106
160. Døssing H, Bennedbæk FN, Karstrup S, Hegedüs L. Benign solitary solid cold thyroid nodules: US-guided interstitial laser photocoagulation-initial experience. *Radiology*. 2002;225:53-57. doi:10.1148/radiol.2251011042
161. Døssing H, Bennedbæk FN, Hegedüs L. Long-term outcome following interstitial laser photocoagulation of benign cold thyroid nodules. *Eur J Endocrinol*. 2011;165:123-128. doi:10.1530/EJE-11-0220
162. Achille G, Zizzi S, Di Stasio E, Grammatica A, Grammatica L. Ultrasound-guided percutaneous laser ablation in treating symptomatic solid benign thyroid nodules: our experience in 45 patients. *Head Neck*. 2016;38(5):677-682. doi:10.1002/hed.23957
163. Papini E, Rago T, Gambelunghe G, et al. Long-term efficacy of ultrasound-guided laser ablation for benign solid thyroid nodules. Results of a three-year multicenter prospective randomized trial. *J Clin Endocrinol Metab*. 2014;99:3653-3659. doi:10.1210/jc.2014-1826
164. Valcavi R, Riganti F, Bertani A, Formisano D, Pacella CM. Percutaneous laser ablation of cold benign thyroid nodules: a 3-year follow-up study in 122 patients. *Thyroid*. 2010;20:1253-1261. doi:10.1089/thy.2010.0189
165. Pacella CM, Mauri G, Achille G, et al. Outcomes and risk factors for complications of laser ablation for thyroid nodules: a multicenter study on 1531 patients. *J Clin Endocrinol Metab*. 2015;100:3903-3910. doi:10.1210/jc.2015-1964
166. Døssing H, Bennedbæk FN, Bonnema SJ, Grupe P, Hegedüs L. Randomized prospective study comparing a single radioiodine dose and a single laser therapy session in autonomously functioning thyroid nodules. *Eur J Endocrinol*. 2007;157:95-100. doi:10.1530/EJE-07-0094
167. Pacella CM, Mauri G. Is there a role for minimally invasive thermal ablations in the treatment of autonomously functioning thyroid nodules? *Int J Hyperthermia*. 2018;34:636-638. doi:10.1080/02656736.2018.1462537
168. Zhou W, Ni X, Xu S, Zhang L, Chen Y, Zhan W. Ultrasound-guided laser ablation versus surgery for solitary papillary thyroid microcarcinoma: a retrospective study. *Int J Hyperthermia*. 2019;36:897-904. doi:10.1080/02656736.2019.1649475
169. Tong M, Li S, Li Y, Li Y, Feng Y, Che Y. Efficacy and safety of radiofrequency, microwave and laser ablation for treating papillary thyroid microcarcinoma: a systematic review and meta-analysis. *Int J Hyperthermia*. 2019;36:1278-1286. doi:10.1080/02656736.2019.1700559
170. Morelli F, Sacrini A, Pompili G, et al. Microwave ablation for thyroid nodules: a new string to the bow for percutaneous treatments? *Gland Surg*. 2016;5:553-558. doi:10.21037/gs.2016.12.07
171. Zheng BW, Wang JF, Ju JX, Wu T, Tong G, Ren J. Efficacy and safety of cooled and uncooled microwave ablation for the treatment of benign thyroid nodules: a systematic review and meta-analysis. *Endocrine*. 2018;62:307-317. doi:10.1007/s12020-018-1693-2
172. Jin H, Fan J, Liao K, He Z, Li W, Cui M. A propensity score matching study between ultrasound-guided percutaneous microwave ablation and conventional thyroidectomy for benign thyroid nodules treatment. *Int J Hyperthermia*. 2018;35:232-238. doi:10.1080/02656736.2018.1492028
173. Zhi X, Zhao N, Liu Y, Bin LJ, Teng C, Qian L. Microwave ablation compared to thyroidectomy to treat benign thyroid nodules. *Int J Hyperthermia*. 2018;34:644-652. doi:10.1080/02656736.2018.1456677
174. Yan J, Qiu T, Lu J, Wu Y, Yang Y. Microwave ablation induces a lower systemic stress response in patients than open surgery for treatment of benign thyroid nodules. *Int J Hyperthermia*. 2018;34:606-610. doi:10.1080/02656736.2018.1427286
175. Lang BHH, Wu ALH. High intensity focused ultrasound (HIFU) ablation of benign thyroid nodules—a systematic review. *J Ther Ultrasound*. 2017;5:11. doi:10.1186/s40349-017-0091-1
176. Monpeyssen H, Ben Hamou A, Hegedüs L, et al. High-intensity focused ultrasound (HIFU) therapy for benign thyroid nodules: a 3-year retrospective multicenter follow-up study. *Int J Hyperthermia*. 2020;37:1301-1309. doi:10.1080/02656736.2020.1846795
177. Sennert M, Happel C, Korkusuz Y, Grünwald F, Polenz B, Gröner D. Further investigation on high-intensity focused ultrasound (HIFU) treatment for thyroid nodules: effectiveness related to baseline volumes. *Acad Radiol*. 2018;25:88-94. doi:10.1016/j.acra.2017.07.011
178. Lang BHH, Woo YC, Chiu KWH. Single-session high-intensity focused ultrasound treatment in large-sized benign thyroid nodules. *Thyroid*. 2017;27:714-721. doi:10.1089/thy.2016.0664
179. Lang BHH, Wong CKH, Ma EPM. Single-session high intensity focussed ablation (HIFU) versus open cervical hemithyroidectomy for benign thyroid nodule: analysis on early efficacy, safety and voice quality. *Int J Hyperthermia*. 2017;33:868-874. doi:10.1080/02656736.2017.1305127
180. Giovannella L, Piccardo A, Pezzoli C, et al. Comparison of high intensity focused ultrasound and radioiodine for treating toxic thyroid nodules. *Clin Endocrinol (Oxf)*. 2018;89:219-225. doi:10.1111/cen.13738

181. Gharib H, Papini E, Garber JR, et al. American Association of Clinical Endocrinologists, American college of endocrinology, and Associazione Medici Endocrinologi medical guidelines for clinical practice for the diagnosis and management of thyroid nodules—2016 update. *Endocr Pract.* 2016;22:622-639. doi:10.4158/EP161208.GL
182. Bennedbæk FN, Hegedüs L. Percutaneous ethanol injection therapy in benign solitary solid cold thyroid nodules: a randomized trial comparing one injection with three injections. *Thyroid.* 1999;9:225-233. doi:10.1089/thy.1999.9.225
183. Ferreira MC, Piaia C, Cadore AC. Percutaneous ethanol injection versus conservative treatment for benign cystic and mixed thyroid nodules. *Arch Endocrinol Metab.* 2016;60:211-216. doi:10.1590/2359-3997000000120
184. Valcavi R, Frasoldati A. Ultrasound-guided percutaneous ethanol injection therapy in thyroid cystic nodules. *Endocr Pract.* 2004;10:269-275. doi:10.4158/EP.10.3.269
185. Kim SY, Kim SM, Chang H, et al. Long-term outcomes of ethanol injection therapy for locally recurrent papillary thyroid cancer. *Eur Arch Oto-Rhino-Laryngology.* 2017;274:3497-3501. doi:10.1007/s00405-017-4660-2
186. Hay ID, Lee RA, Davidge-Pitts C, Reading CC, Charboneau JW. Long-term outcome of ultrasound-guided percutaneous ethanol ablation of selected “recurrent” neck nodal metastases in 25 patients with TNM stages III or IVA papillary thyroid carcinoma previously treated by surgery and 131I therapy. *Surg (United States).* 2013;154:1448-1454. doi:10.1016/j.surg.2013.07.007
187. Deandrea M, Garino F, Alberto M, et al. Radiofrequency ablation for benign thyroid nodules according to different ultrasound features: an Italian multicentre prospective study. *Eur J Endocrinol.* 2019;180:79-87. doi:10.1530/EJE-18-0685
188. Chung SR, Baek JH, Choi YJ, Lee JH. Management strategy for nerve damage during radiofrequency ablation of thyroid nodules. *Int J Hyperthermia.* 2019;36:204-210. doi:10.1080/02656736.2018.1554826
189. Wu Y, Jia JP, Xu M, et al. Role of nitric oxide in pathogenesis of cold nerve injury. *Natl Med J China.* 2009;89:2214-2220. doi:10.3760/cma.j.issn.0376-2491.2009.31.015
190. Esposito RA, Spencer FC. The effect of pericardial insulation on hypothermic phrenic nerve injury during open-heart surgery. *Ann Thorac Surg.* 1987;43:303-308. doi:10.1016/S0003-4975(10)60619-4
191. Chung SR, Baek JH, Sung JY, Ryu JH, Jung SL. Revisiting rupture of benign thyroid nodules after radiofrequency ablation: various types and imaging features. *Endocrinol Metab.* 2019;34:415-421. doi:10.3803/EnM.2019.34.4.415
192. Baek JH, Lee JH, Sung JY, et al. Complications encountered in the treatment of benign thyroid nodules with us-guided radiofrequency ablation: a multicenter study. *Radiology.* 2012;262:335-342. doi:10.1148/radiol.11110416
193. Shin JH, Jung SL, Baek JH, Kim JH. Rupture of benign thyroid tumors after radio-frequency ablation. *Am J Neuroradiol.* 2011;32:2165-2169. doi:10.3174/ajnr.A2661
194. van Baardewijk LJ, Plaisier ML, van den Broek FJC, van Poppel PCMW, Kurban S, Kruimer JWH. Tracheal necrosis following radiofrequency ablation of a benign thyroid nodule. *Cardiovasc Intervent Radiol.* 2021;44(1):170-171. doi:10.1007/s00270-020-02632-0
195. Kumar A, Kugler J, Jensen T. Evaluation of trainee competency with point-of-care ultrasonography (POCUS): a conceptual

framework and review of existing assessments. *J Gen Intern Med.* 2019;34:1025-1031. doi:10.1007/s11606-019-04945-4

196. Martín-Hernández T, Díez Gómez JJ, Díaz-Soto G, et al. Consensus statement for use and technical requirements of thyroid ultrasound in endocrinology units. *Endocrinol Diabet Nutr.* 2017;64:23-30. doi:10.1016/j.endinu.2016.10.007

## SUPPORTING INFORMATION

Additional supporting information may be found in the online version of the article at the publisher's website.

**How to cite this article:** Orloff LA, Noel JE, Stack BC Jr, et al. Radiofrequency ablation and related ultrasound-guided ablation technologies for treatment of benign and malignant thyroid disease: An international multidisciplinary consensus statement of the American Head and Neck Society Endocrine Surgery Section with the Asia Pacific Society of Thyroid Surgery, Associazione Medici Endocrinologi, British Association of Endocrine and Thyroid Surgeons, European Thyroid Association, Italian Society of Endocrine Surgery Units, Korean Society of Thyroid Radiology, Latin American Thyroid Society, and Thyroid Nodules Therapies Association. *Head & Neck.* 2022;44(3): 633-660. doi:10.1002/hed.26960

## APPENDIX: PubMed SEARCH STRATEGY

Search 1:

(Thyroid Gland[MeSH] OR Thyroid Neoplasms[MeSH] OR Thyroid Diseases[MeSH] OR Thyroid Carcinoma, Anaplastic[MeSH] OR thyroid[ti])

Search 2:

Ablation Techniques[MeSH] OR High-intensity focused ultrasound ablation[MeSH] OR Radiofrequency Ablation[MeSH] OR Catheter Ablation[MeSH] OR Laser Therapy[MeSH] OR Ultrasonic Surgical Procedures[MeSH] OR Argon Plasma Coagulation[MeSH] OR Radiofrequency Therapy[MeSH] OR ablat\*[ti] OR ((ethanol[ti] OR alcohol [ti]) AND inject[tiab])

Search 3:

#1 AND #2

Search 4:

#3 NOT (animals[MeSH] NOT humans[MeSH])

PMID's for sentinel articles: 29962870 26782174 28565997 29490593 26980591 28797186 21927553 3088774